5

Spondyloarthropathies

MUHAMMAD ASIM KHAN

Spondyloarthropathies constitute a cluster of interrelated and overlapping chronic inflammatory rheumatic diseases that include ankylosing spondylitis (the prototype of spondyloarthropathies), reactive arthritis (including Reiter's syndrome), psoriatic arthritis, enteropathic arthritis, and pauciarticular late-onset arthritis, a form of juvenile idiopathic arthritis [1–5]. These diseases are not associated with rheumatoid factor. They occur in genetically predisposed individuals and show a strong association with HLA-B27; however, the strength of the association with HLA-B27 varies markedly among the patients with the various forms of spondyloarthropathies, and also among many racial and ethnic groups [6–9]. Bacterial infections have long been suspected as the environmental triggers for many of these diseases, but the cellular and molecular mechanisms of inflammation are not yet fully understood. Chlamydial and many enterobacterial infections can trigger reactive arthritis, but an infectious trigger for ankylosing spondylitis has not yet been established [2].

Substantial evidence strongly favors a direct role for HLA-B27 in enhancing genetic susceptibility, and a few additional genetic factors may also influence the susceptibility, disease expression, or severity [9–16]. Some of these additional genetic predisposing factors may include some of the putative disease-predisposing genes for psoriasis and inflammatory bowel disease.

Spondyloarthropathies are more prevalent among males than females. The patients are usually in their late teens and early twenties at the time of disease onset, although spondyloarthropathies may sometimes present at an older age [2,17,18]. The primary pathologic sites include the entheses, which are the sites of bony insertion of ligaments and tendon, the sacroiliac joints and the axial skeleton, the limb joints, and some nonarticular structures, such as the gut, skin, eye, and aortic valve [19–21]. The initial clinical features may result from enthesitis (inflammatory lesions of the entheses), dactylitis, or oligoarthritis, and in some cases may progress to sacroiliitis and spondylitis, with or without extra-articular features such as acute anterior uveitis or mucocutaneous lesions.

It may not always be possible to differentiate clearly among the various forms of spondyloarthropathies in early stages because these diseases generally share many clinical features. Moreover, the clinical spectrum is much wider than previously realized, and the clinical features typical of spondyloarthropathies may occur in different combinations so that the previously established criteria for disease classification may be inappropriate for a large subset of such patients [17,18].

Some additional less clearly defined categories are being recognized, and some of them are grouped under the label of "undifferentiated" spondyloarthropathies [2,3,17,18,22,23]. The frequently underdiagnosed "undifferentiated" forms of spondyloarthropathies include isolated clinical syndromes, such as HLA-B27–associated seronegative oligoarthritis or polyarthritis, mostly of the lower extremities, without a recognizable preceding bacterial infectious trigger and any extra-articular clinical features, or associated inflammatory bowel disease or psoriasis. Some patients present with dactylitis ("sausage digits") or enthesitis, especially at the heel (Achilles tendonitis and plantar fasciitis) (acute iritis) [2,18,21–25]. These may occur even in early childhood or in persons over age 50 [2,5,18].

Approximately 50% of white patients with acute anterior uveitis are HLA-B27–positive, and well over half of the patients with HLA-B27–positive acute anterior uveitis have some form of spondyloarthropathy [24,25]. An HLA-B27–associated syndrome of aortic incompetence plus heart block has also been described [26]. These extra-articular manifestations may occur in individuals with no signs of arthritis or may accompany the onset of spondyloarthropathy or occur many years later. A clear differentiation between the various forms of spondyloarthropathies, especially in their early stages, may not always be possible due to their overlapping clinical features.

Studies from Western Europe indicate that ankylosing spondylitis in its full spectrum is much more common than previously realized, and its overall prevalence may be similar to that of rheumatoid arthritis [2,27–29]. Moreover, the prevalence figure for spondyloarthropathies as a whole may be approximately twice as high; this is especially the case in the Eskimo and the Inuit populations that have a 25% to 40% prevalence of HLA-B27 in the

general population [2,22]. Conversely, spondyloarthropathies are relatively rare among the Japanese population, with a very low (< 1%) general prevalence of HLA-B27 [30]. A sharp increase in the prevalence of spondyloarthropathies has been observed recently in sub-Saharan African countries in association with the high prevalence of HIV infection [31].

The European Spondyloarthropathy Study Group (*see* Fig. 5-2) and Amor (*see* Fig. 5-3) classification criteria have been developed to encompass the wider spectrum of spondyloarthropathies [32–36].

There are 25 different currently known natural variants of the HLA-B27 molecule. They show different ethnic distributions, and some of them may also show differences in disease association [7,10,15]. For example, HLA-B*2706 in Southeast Asians and HLA-B*2709 in Sardinian Italians seem to lack association with ankylosing spondylitis [10,37–39].

Ankylosing spondylitis is generally considered to be the most common and most typical form of spondyloarthropathy. It is a chronic systemic inflammatory disorder of undetermined etiology, usually beginning in early adulthood, primarily affecting the axial skeleton (sacroiliitis being its hallmark), but it can also exhibit some extra-articular features [2,3,40]. The inflammation appears to originate in ligamentous and capsular sites of attachment to bones (enthesitis), juxta-articular ligamentous structures, and the synovium, articular cartilage, and subchondral bones of involved joints [19–21,41–46]. The site of enthesitis is infiltrated by lymphocytes, plasma cells, and polymorphonuclear cells, and there is also edema and infiltration of the adjacent marrow space. A striking feature is a high frequency of axial enthesitis and synovitis that can result in fibrous and later bony ankylosis of the sacroiliac joints and the spine. It is two to three times more common in males than females, and the clinical and roentgenographic features seem to evolve more slowly in females. The characteristic early symptom is insidious onset of chronic low back pain and stiffness, beginning usually in late adolescence or early adulthood (mean age of onset, 24 years), but a variety of presentations may antedate back symptoms in some patients [2,40]. It is rare for ankylosing spondylitis to begin after 45 years of age [18,36], but there are many patients whose disease gets diagnosed at an older age, in part because they may have had minimal symptoms over the years.

The pain resulting from sacroiliitis is dull in character, difficult to localize, and felt somewhere deep in the gluteal region. It may be unilateral or intermittent at first; however, within a few months it generally becomes persistent and bilateral, and the lower lumbar spine area also becomes painful. Sometimes pain in the lumbar area may be the initial presentation. The symptoms typically worsen with prolonged inactivity or on waking up in the morning ("morning stiffness"), and improve with physical activity and a hot shower.

The diagnosis of ankylosing spondylitis is clinical, but the historic features suggestive of chronic inflammatory back pain, *ie*, its insidious onset before the age of 40, its worsening with inactivity and improvement on physical exercise, are not very specific on their own [4,47,48]. A history of acute anterior uveitis, a positive family history for ankylosing spondylitis or related spondyloarthropathies, or the presence of impaired spinal mobility or chest expansion further supports the clinical diagnosis. So does the presence of enthesitis with resultant tenderness over the sacroiliac joints and the spine, and sometimes at other sites, such as the heels, iliac crest, and the anterior chest wall. The modified New York criteria for ankylosing spondylitis are now commonly used for disease classification [49,50].

Reactive arthritis is defined as an episode of aseptic asymmetric peripheral arthritis, predominantly of the lower limbs, occurring within a month of a primary infection elsewhere in the body, usually genitourinary infection with *Chlamydia trachomatis* or an enteritis due to certain gram-negative enterobacteria [51–56]. It is frequently associated with one or more characteristic extra-articular features, such as ocular inflammation (conjunctivitis or acute iritis), enthesitis (Achilles tendonitis and plantar fasciitis), dactylitis ("sausage" digits), tenosynovitis, mucocutaneous lesions, urethritis, and, on rare occasions, carditis. The enteritis results from infection with bacteria such as *Shigella, Salmonella, Yersinia,* or *Campylobacter* (*see* Fig. 5-32). The reactive arthritis can also follow local injection of Bacille Calmette-Guérin (BCG) into the bladder as cancer therapy [57], but not with BCG inoculation that is used in some countries to decrease the risk of tuberculosis. It has been suggested that respiratory tract infections by *Chlamydia pneumoniae* may also trigger reactive arthritis [58]. The disease is most commonly seen in young sexually active adults, mostly men, when it is triggered by *C. trachomatis*. However, reactive arthritis is underdiagnosed in women due to the frequently subclinical or asymptomatic chlamydial infection among them and the infrequent performance of pelvic examinations by physicians to look for the presence of cervicitis. Postenteritic reactive arthritis affects children and adults, including the elderly, of both genders.

Urethritis and cervicitis can accompany arthritis after acute bacterial diarrhea; and, conversely, the psoriasiform lesions over the external genitalia (circinate balanitis and circinate vulvitis) do not directly relate to the presence of genitourinary infection. In about one quarter of all cases the triggering organism remains unknown.

A history of a preceding or associated diarrhea, urethral discharge, urinary frequency, dysuria, lower abdominal discomfort, tender enlarged prostate, circinate balanitis, conjunctivitis, mucosal lesions, onycholysis, or keratoderma blennorrhagica should suggest the possibility of reactive arthritis [55,59,60]. Septic arthritis should be ruled out by joint aspiration, Gram's stain, and culture of any accessible joint fluid. Conjunctivitis occurs in one third of patients with reactive arthritis, usually in synchrony with flares of arthritis, and some patients experience one or more episodes of acute anterior uveitis. The triad of arthritis, conjunctivitis, and urethritis has been called *Reiter's syndrome*, but most patients with reactive arthritis do not present with this triad. The full clinical spectrum of reactive arthritis has been broadened considerably, and "incomplete" forms are

observed much more commonly than the classic triad. Some patients may not demonstrate any recognized antecedent infection or may have asymptomatic triggering infection, and reactive arthritis–associated bacteria may trigger some forms of the undifferentiated spondyloarthropathies and juvenile arthritis.

The average duration of the arthritis is 4 to 5 months, but many patients have mild musculoskeletal symptoms persisting for more than a year. HLA-B27–positive patients tend to have more severe and more prolonged joint symptoms [53,55,60]. Recurrent attacks are more common in those with chlamydia-induced reactive arthritis. Approximately 15% to 30% develop chronic or recurrent arthritis or sacroiliitis and spondylitis, and these patients are mostly those with a positive family history or are positive for HLA-B27, and often have severe and more chronic disease.

Severe arthritis, or an illness resembling typical reactive arthritis, psoriatic arthritis, or undifferentiated spondyloarthropathy, can occur in some patients infected with HIV [31,61–63], but it seems to have become less common in developed countries due to the availability of more effective antiviral therapies. Since the advent of the current HIV epidemic, reactive arthritis, psoriasis, psoriatic arthritis, and related spondyloarthropathies, except ankylosing spondylitis, are becoming more prevalent in sub-Saharan Africa, where these diseases used to be extremely rare [31]. For example, the prevalence of spondyloarthropathies in Lusaka, the capital of Zambia, now has been calculated to be approximately 180 per 100,000 in HIV-infected individuals, 12 times higher than in the population uninfected with HIV [31,63]. Such patients are also prone to bone and joint infections due to their low CD4+ T-cell count.

Psoriasis is a common skin disease among whites (1% to 3% prevalence), and is even more common (5% to 10%) in northernmost regions of Norway and Russia, but it is uncommon in some other racial groups, such as blacks and native Americans (0% to 0.3%) [64]. More than 10% (range, 5% to 42%) of patients with psoriasis have associated inflammatory arthritis, including sacroiliitis and spondylitis [65]. Psoriasis usually antedates the appearance of arthritis by one to two decades. The arthritis usually begins between 30 and 50 years of age, but it can also begin in childhood. A search for psoriasis in an arthritis patient suspected to have psoriatic arthritis should not be limited to the extremities but also should include the scalp, ears, umbilicus, pelvic area, perineum, natal cleft (perianal area), palms, soles, and nails.

Psoriatic arthritis is defined as an inflammatory arthritis associated with psoriasis, occurring in the absence of rheumatoid nodules and serum rheumatoid factor [64–67]. Different subtypes of psoriatic arthritis have been proposed: monoarthritis and oligoarthritis, polyarthritis, arthritis of distal interphalangeal joints with nail changes, arthritis mutilans, and spondylitis. However, psoriatic arthritis runs a very variable course, and the distinction between these subtypes becomes less distinct with time and there are no universal criteria for its diagnosis. A subset of patients may show peripheral enthesitis without arthritis. The exact prevalence of each of these various forms is difficult to establish because the pattern in some patients may change with time, and some may show overlapping features.

The evolution of a mild psoriasis to a widespread erythrodermic pattern with an associated flare-up of arthritis may raise the possibility of an associated HIV infection. There has been a dramatic increase of psoriasis and psoriatic arthritis in sub-Saharan Africa, associated with the current epidemic of HIV infection [31,61–63]. Among a cohort of 702 patients with inflammatory arthritis in Zambia, 28 had psoriatic arthritis and all but one (96%) were HIV positive [63], suggesting that every patient with newly diagnosed psoriatic arthritis in sub-Saharan Africa should be tested for possible HIV infection.

The term *enteropathic arthritis* implies the occurrence of inflammatory arthritis in patients with ulcerative colitis and Crohn's disease. It is more common than previously reported; 39% of 103 patients with ulcerative colitis or Crohn's disease, irrespective of the extent of the bowel disease, had enteropathic arthritis [68]. Inflammatory back pain was present in 30% of these 103 patients, and 10% fulfilled the criteria for ankylosing spondylitis. The inflammatory arthritis of peripheral (limb) joints tends to occur much more frequently in enteropathic arthritis than with primary ankylosing spondylitis, but it tends to be self-limited and nondeforming, and correlates with flare-up of bowel disease, especially in the case of ulcerative colitis. The axial disease (sacroiliitis alone or with classic clinical and radiographic features of ankylosing spondylitis) does not fluctuate with bowel disease activity.

An increased frequency of subclinical inflammatory lesions in the gut (20% to 70%) is observed on colonoscopic mucosal biopsy in patients with spondyloarthropathy who have no gastrointestinal symptoms or clinically obvious inflammatory bowel disease [69,70]. Follow-up studies of such patients indicate that 6% of them will develop inflammatory bowel disease, and among those with histologically "chronic" inflammatory gut lesions, between 15% and 25% will develop clinically obvious Crohn's disease. This suggests that the latter group of patients had initially a subclinical form of Crohn's disease when they presented with arthritis [69,70].

Juvenile spondyloarthropathy begins before the age of 16, mostly in boys aged 9 years or older, and the common presentation is that of a seronegative oligoarthritis of the lower extremities, frequently with enthesitis [5,71]. Recent epidemiologic studies suggest that this disease may be much more prevalent than previously realized. There may be no clinically or roentgenographically identifiable involvement of the sacroiliac joints or the spine in these patients, and they may also lack any inflammatory back symptoms, mucocutaneous lesions, or gastrointestinal problems in early stages. Therefore, they may be misclassified as having a late-onset form of pauciarticular juvenile chronic arthritis.

THE CONCEPT OF SPONDYLOARTHROPATHY

Disease Subgroups

1. Ankylosing spondylitis
2. Reactive arthritis (Reiter's syndrome)
3. Enteropathic arthritis
4. Psoriatic arthritis
5. Undifferentiated spondyloarthropathy
6. Juvenile spondyloarthropathy

All These Diseases Share Rheumatologic Features

- Sacroiliac and spinal (axial) involvement
- Enthesitis at long attachments of ligaments and tendons causing: Achilles tendonitis and plantar fasciitis, syndesmophyte formation ("bamboo spine"), sacroiliitis (due to a combination of enthesitis and synovitis), and periosteal reaction ("whiskering") at gluteal tuberosity and other parts of pelvis and other sites
- Peripheral, often asymmetric, inflammatory arthritis and dactylitis ("sausage" digits)

Share Extra-articular Features

- Propensity to ocular inflammation (acute anterior uveitis conjunctivitis)
- Mucocutaneous lesions, variable for the subgroups
- Rare aortic incompetence or heart block
- Lack of association with rheumatoid factor and rheumatoid nodules

Share Genetic Predisposition

- Strong association with HLA-B27 gene
- Familial clustering

FIGURE 5-1. The concept of spondyloarthropathy. The clinical spectrum of the rheumatologic diseases included under the term *spondyloarthropathies* consists of ankylosing spondylitis, reactive arthritis or Reiter's syndrome, spondyloarthritis associated with psoriasis and chronic inflammatory bowel diseases, and a form of juvenile chronic arthritis (pauciarticular, late-onset type) [1–5]. All forms of the spondyloarthropathies are associated with the histocompatibility antigen HLA-B27, although the strength of this association varies markedly not only among the various disease forms but also among the various ethnic and racial groups worldwide [6–10]. These diseases tend to occur more often among young men who are in their late teens and early twenties and may start with features such as enthesitis (inflammatory lesions of the entheses, *ie*, sites of ligamentous or tendinous attachments to bone) or dactylitis oligoarthritis. The disease may progress to sacroiliitis and spondylitis, with or without extra-articular features such as acute anterior uveitis or mucocutaneous lesions [2,17,18]. The clinical features typical of the spondyloarthropathies may occur in different combinations so that the existing classification criteria may be inappropriate for a subset of such patients. For example, there are now well-defined HLA-B27–associated clinical syndromes such as seronegative oligoarthritis or polyarthritis (mostly affecting joints of the lower extremities), dactylitis, and enthesitis (plantar fasciitis or calcaneal periostitis, Achilles tendonitis, and tenderness of tibial tubercles). The overall prevalence of this form of undifferentiated spondyloarthropathy may be higher than that of reactive arthritis in some parts of the world [2,17,18,22,23].

EUROPEAN SPONDYLOARTHROPATHY STUDY GROUP CRITERIA FOR SPONDYLOARTHROPATHY

Inflammatory Spinal Pain	or	Synovitis
		Asymmetric *or* Predominantly in lower limbs

plus

One or more of the following:

Alternate buttock pain
Sacroiliitis
Enthesopathy
Positive family history
Psoriasis
Inflammatory bowel disease
Urethritis or cervicitis or acute diarrhea occurring within 1 mo before onset of arthritis

FIGURE 5-2. Criteria for spondyloarthropathy. Features typical of the spondyloarthropathies may occur in various combinations, and it was recognized a few years ago that the available disease criteria are inadequate for many patients. Therefore, new classification criteria were proposed by the European Spondyloarthropathy Study Group to encompass the currently recognized wider spectrum [32]. These criteria have a high degree of sensitivity and specificity, but they cannot be used to help in identifying patients who have either an isolated peripheral arthritis, dactylitis, enthesitis, inflammatory spinal pain, acute anterior uveitis, or aortic insufficiency with heart block as the only clinical manifestation of the disease.

AMOR CRITERIA FOR SPONDYLOARTHROPATHY

Parameter	Scoring
A. Clinical symptoms or past history of	
1. Lumbar or dorsal pain at night or morning stiffness of lumbar or dorsal region	1
2. Asymmetric oligoarthritis	2
3. Buttock pain	1
	or
if alternate buttock pain	2
4. Sausage-like toe or digit	2
5. Heel pain or other well-defined enthesiopathic pain	2
6. Iritis	2
7. Nongonococcal urethritis or cervicitis within 1 mo before the onset of arthritis	1
8. Acute diarrhea within 1 mo before the onset of arthritis	1
9. Psoriasis, balanitis, or IBD (ulcerative colitis or Crohn's disease)	2
B. Radiologic findings	
10. Sacroiliitis (bilateral grade 2 or unilateral grade 3)	2
C. Genetic background	
11. Presence of HLA-B27 or family history of ankylosing spondylitis, reactive arthritis, uveitis, psoriasis, or IBD	2
D. Response to treatment	
12. Clear-cut improvement within 48 h after NSAID intake or rapid relapse of the pain after their discontinuation	2

A patient is considered to be suffering from a spondyloarthropathy if the sum is ≥ 6.

FIGURE 5-3. Amor criteria for spondyloarthropathy. The Amor multiple entry criteria system has one advantage over the European Spondyloarthropathy Study Group (ESSG) criteria in that the patients with undifferentiated spondyloarthropathy without arthritis or inflammatory back pain can be classified as having a form of spondyloarthropathy with the Amor citeria but not the European criteria [71]. No single item in the criteria list can contribute the six points needed to classify the patient as having spondyloarthropathy. Relief of pain within 24 to 48 hours after initiating treatment with a nonsteroidal anti-inflammatory drug (NSAID) or recurrence of pain within 24 to 48 hours after discontinuation of this treatment is of greater clinical usefulness (two points). For this component to be valid, the dosage of the NSAID should be large enough (ie, anti-inflammatory dose) and the dosage regimen sufficient to have appropriate therapeutic anti-inflammatory blood levels in the morning. IBD—inflammatory bowel disease.

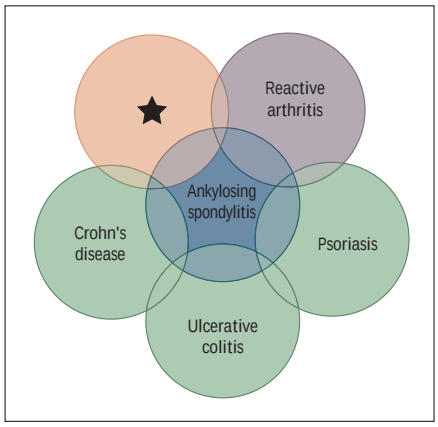

FIGURE 5-4. Venn diagram showing overlap among various spondyloarthropathies. The *star* denotes juvenile and undifferentiated spondyloarthropathies. The intensity of the *shaded area* indicates association with HLA-B27; the strongest association is with primary ankylosing spondylitis (represented by the nonoverlapped central part of the central circle). Note that psoriasis, ulcerative colitis, and Crohn's disease in the absence of associated spondyloarthropathy do not show any association with HLA-B27.

RECENT PREVALENCE STUDIES OF ANKYLOSING SPONDYLITIS AND RELATED SPONDYLOARTHROPATHIES

		Prevalence of AS, %		Prevalence of SpA (including AS), %	
Populations	B27 Frequency, %	General Population	B27(+) Population	General Population	B27(+) Population
Eskimos (Alaska)	40	0.4		2.5	
Eskimos (Alaska and Siberia) + Chukchi	25–40		1.6	2–3.4	4.2
Saamis (Lapland)	24	1.8	6.8		
Northern Norway	14	1.4	6.7		
Mordovia	16	0.5			
Holland	8	0.2	2		
Germany	9	0.86	6.4	1.9	13.6

FIGURE 5-5. Prevalence studies of ankylosing spondylitis (AS) and related spondyloarthropathies (SpA). Recent studies in the native populations of Siberia (Chukchi and Eskimo) and Alaska (Inupiaq and Yupik Eskimo) that have a very high prevalence of HLA-B27 (25% to 40%) show an overall prevalence of spondyloarthropathies (between 2% and 3.4%) [72]. This figure similarly lists the data derived from the recent epidemiologic studies in other populations [3,72].

CLASSIFICATION FOR ANKYLOSING SPONDYLITIS

Rome, 1961

Clinical criteria
1. Low back pain and stiffness for more than 3 mo, not relieved by rest
2. Pain and stiffness in the thoracic region
3. Limited motion in the lumbar spine
4. Limited chest expansion
5. History or evidence of iritis or its sequelae

Radiologic criterion
1. Roentgenogram showing bilateral sacroiliac changes characteristic of ankylosing spondylitis (this would exclude bilateral osteoarthritis of the sacroiliac joints)

Definite ankylosing spondylitis if:
1. Grade 3–4 bilateral sacroiliitis with at least one clinical criterion
2. At least four clinical criteria

New York, 1966

Clinical criteria
1. Limitation of motion of the lumbar spine in all three planes: anterior flexion, lateral flexion, and extension
2. Pain at the dorsolumbar junction or in the lumbar spine
3. Limitation of chest expansion to 2.5 cm or less measured at the level of the fourth intercostal space

Grading of radiographs
Normal, 0; suspicious, 1; minimal sacroiliitis, 2; moderate sacroiliitis, 3; ankylosis, 4

Definite ankylosing spondylitis if:
1. Grade 3–4 bilateral sacroiliitis with at least one clinical criterion
2. Grade 3–4 unilateral or grade 2 bilateral sacroiliitis with clinical criterion 1 or with both clinical criteria 2 and 3

Probable ankylosing spondylitis if:
Grade 3–4 bilateral sacroiliitis with no clinical criteria

Modified New York, 1984

Clinical criteria
1. Low back pain of at least 3 mo duration improved by exercise and not relieved by rest
2. Limitation of lumbar spine in sagittal and frontal planes
3. Chest expansion decreased relative to normal values for age and sex
4. Bilateral sacroiliitis grade 2–4
5. Unilateral sacroiliitis grade 3–4

Definite ankylosing spondylitis if:
Unilateral grade 3 or 4, or bilateral grade 2–4 sacroiliitis and any clinical criterion

Probable ankylosing spondylitis if:
Three clinical criteria present; or radiologic criterion present with no clinical criteria

FIGURE 5-6. Classification criteria for ankylosing spondylitis. These are the widely used diagnostic criteria for ankylosing spondylitis; they greatly depend on the radiographic evidence of sacroiliitis, which is the best nonclinical indicator of the disease presence. However, the status of the sacroiliac joints on routine pelvis radiographs may not always be easy to interpret in the early phase of the disease because of slow evolution in some patients and in adolescent patients. (*Data modified from* van der Linden [73].)

CLINICAL FEATURES OF ANKYLOSING SPONDYLITIS

Skeletal

Axial arthritis, such as sacroiliitis and spondylitis
Arthritis of "girdle joints" (hips and shoulders)
Peripheral arthritis (uncommon)
Others: enthesopathy, osteoporosis, vertebral fractures, spondylodiskitis, pseudoarthrosis

Extraskeletal

Acute anterior uveitis
Cardiovascular involvement
Pulmonary involvement
Cauda equina syndrome
Enteric mucosal lesions
Amyloidosis, miscellaneous

FIGURE 5-7. Clinical features of ankylosing spondylitis. Ankylosing spondylitis is a chronic systemic inflammatory disorder of undetermined etiology, usually beginning in early adulthood, primarily affecting the axial skeleton (sacroiliitis being its hallmark), but can also exhibit some extra-articular features [40]. Patients with ankylosing spondylitis are more prone to osteoporosis [74]. Acute anterior uveitis is the most common extra-articular feature, occurring in 25% to 40% of patients. It occurs relatively more commonly in HLA-B27–positive patients with ankylosing spondylitis than in those who lack this gene [75,76]. The other much less common features include aortic incompetence, heart block, apical pulmonary fibrosis and cavitation, amyloidosis, and IgA nephropathy [2,40]. The marked muscle wasting seen in some patients with advanced disease results from disuse atrophy. Neurologic involvement may occur owing to fracture or dislocation, atlantoaxial subluxation, or cauda equina syndrome [2,77–81].

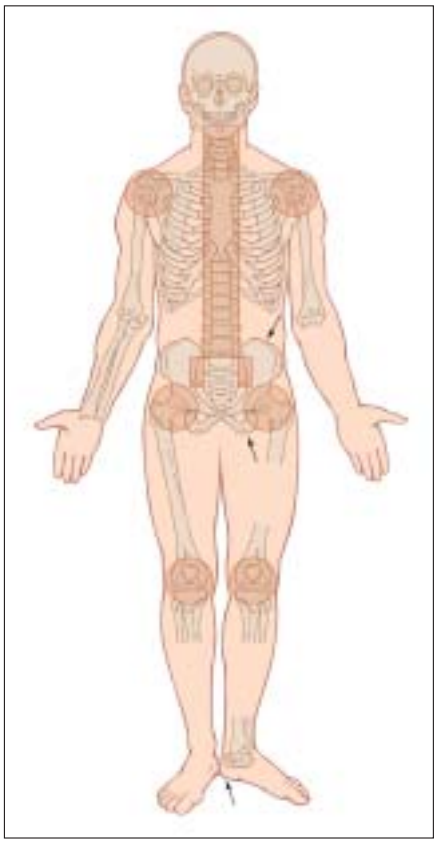

FIGURE 5-8. Sites of inflammation. The inflammation primarily affects the axial skeleton and appears to originate in ligamentous and capsular sites of attachment to bones (enthesitis), juxta-articular ligamentous structures, and the synovium, articular cartilage, and subchondral bones of involved joints [19–21,40,41]. The site of enthesitis is infiltrated by lymphocytes, plasma cells, and polymorphonuclear cells; edema and infiltration of the adjacent marrow space are present. A striking feature is a high frequency of axial enthesitis and synovitis that can result in fibrous and later bony ankylosis of the sacroiliac joints and the spine [45].

Extra-articular or juxta-articular bony tenderness due to enthesitis at costosternal junctions, spinous processes, iliac crests, ischial tuberosities, or heels (*arrows*) may be an early feature of the disease. Stiffness and pain in the cervical spine and tenderness of the spinous processes may occur in early stages of the disease in some patients, but generally this tends to occur after some years. Back symptoms may be absent or very mild in an occasional patient, whereas others may complain only of back stiffness, fleeting muscle aches, or musculotendinous tender spots. These symptoms may be worsened on exposure to cold or dampness, and such patients may occasionally be misdiagnosed as having fibrositis (fibromyalgia). Some may have mild constitutional symptoms such as anorexia, malaise, or mild fever in early disease, and this may be more common among patients with juvenile onset, especially in developing countries. Involvement of the costovertebral and the costotransverse joints and occurrence of enthesitis at costosternal areas may cause chest pain that may be accentuated on coughing or sneezing. Some patients may note their inability to fully expand their chest on inspiration, but moderate to severe pulmonary restriction mostly occurs after long-standing disease.

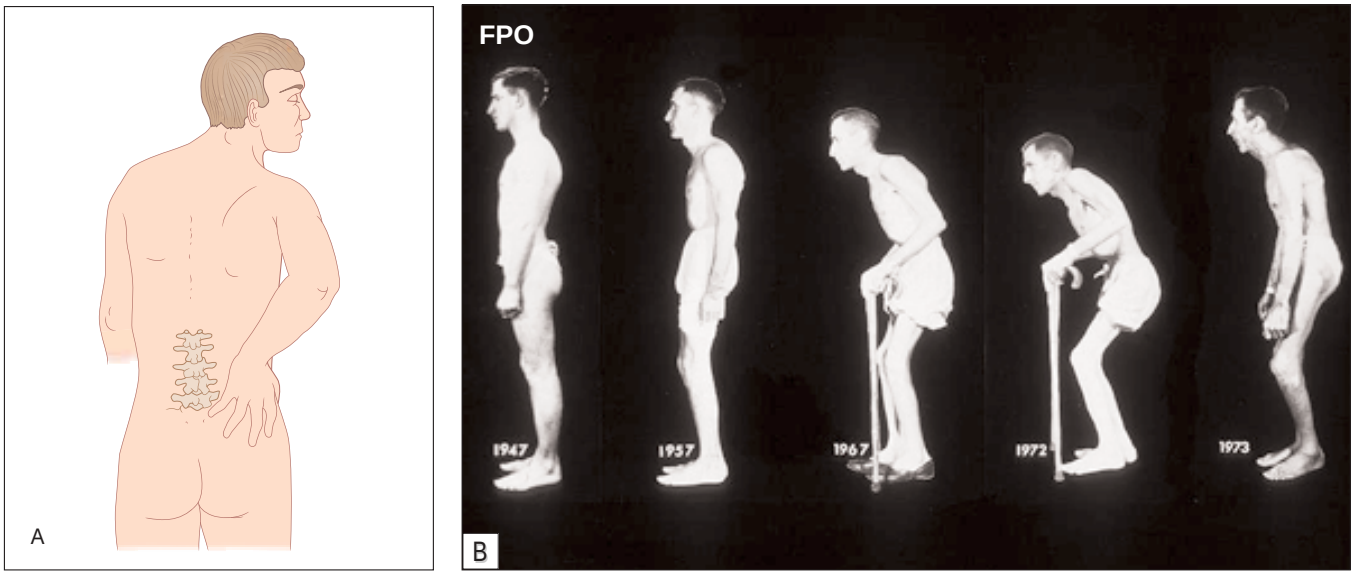

FIGURE 5-9. Early symptoms and progression of ankylosing spondylitis (AS). **A,** The characteristic early symptom is insidious onset of chronic low back pain and stiffness, beginning usually in late adolescence or early adulthood (mean age of onset, 24 years). The pain due to sacroiliitis is dull in character, difficult to localize, and felt somewhere deep in the gluteal region. It may be unilateral or intermittent at first; however, within a few months it generally becomes persistent and bilateral, and the lower lumbar spine area also becomes painful. Sometimes pain in the lumbar area may be the initial presentation. The symptoms typically worsen with prolonged inactivity or on waking up in the morning ("morning stiffness"), and improve with physical activity and a hot shower. The back pain and stiffness may awaken some patients from sleep and some may experience considerable difficulty in getting out of bed in the morning. Others may find it necessary to wake up at night to move about or exercise for a few minutes before returning to bed. Some patients may complain of easy fatiguability, perhaps resulting, in part, from their disturbed sleep pattern. **B,** Progression of AS over a period of 26 years; the patient underwent bilateral total hip arthroplasties in 1973. (**B** *from* Little *et al.* [82]; with permission.)

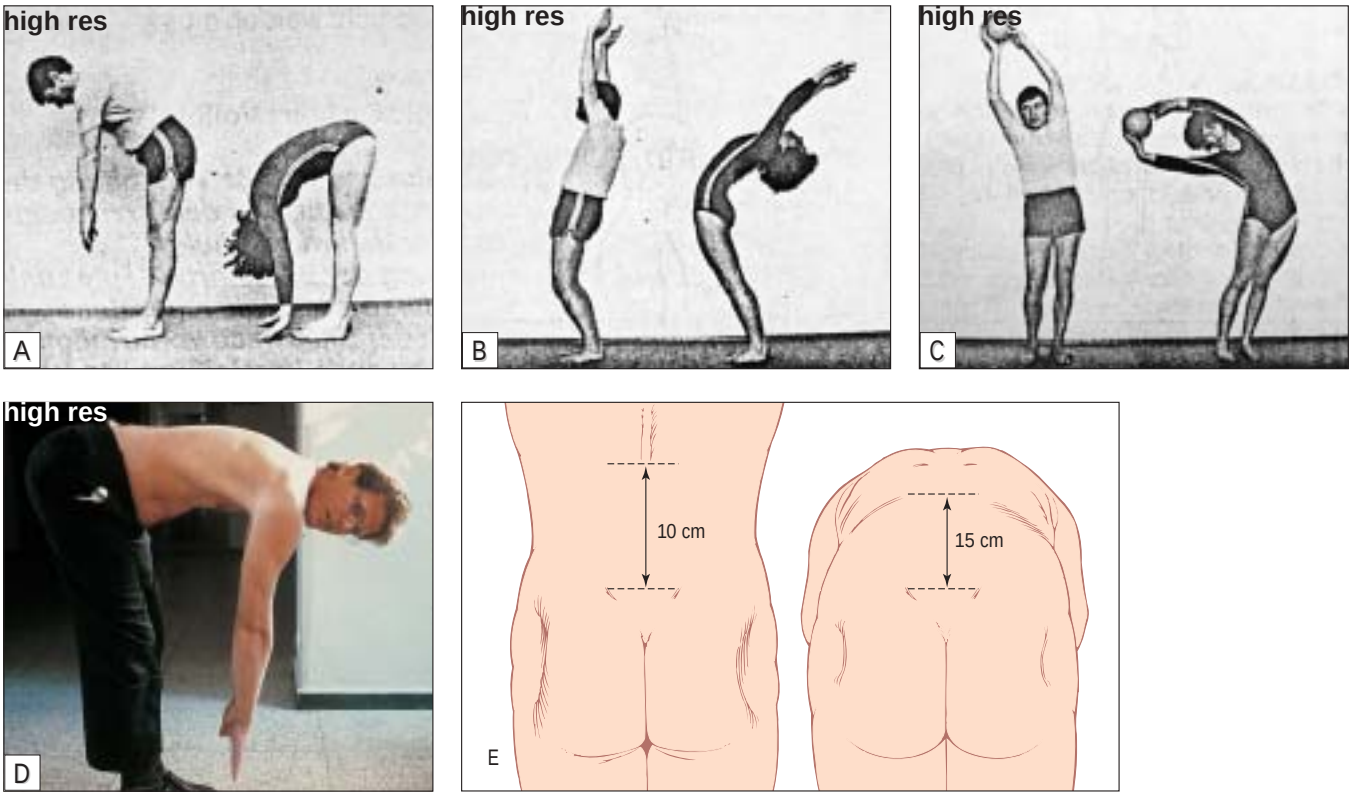

FIGURE 5-10. Tenderness and decreased mobility. Ankylosing spondylitis is diagnosed based on clinical history and physical findings, and the diagnosis is supported by radiographic evidence of sacroiliitis [40,47]. **A** to **D**, Most patients will have decreased spinal mobility (on hyperextension, forward and lateral flexion, and axial rotation). There is often tenderness of the sacroiliac joints or the spine at a relatively early stage of the disease, and there is gradual development of flattening of the lumbar spine (owing to loss of the normal lumbar lordosis). Decreased lumbar spinal flexibility is determined by modified Schober's test (**E**) in which a mark is placed on the skin in the midline of the back at the level of the superior iliac spine. A second mark is placed 10 cm above in midline with the patient standing erect with knees fully extended (**E,F**). The patient is then asked to maximally bend forward without bending the knees. The distance between the two skin marks is stretched to 14 cm or more if spinal flexibility is normal.

(*Continued on next page*)

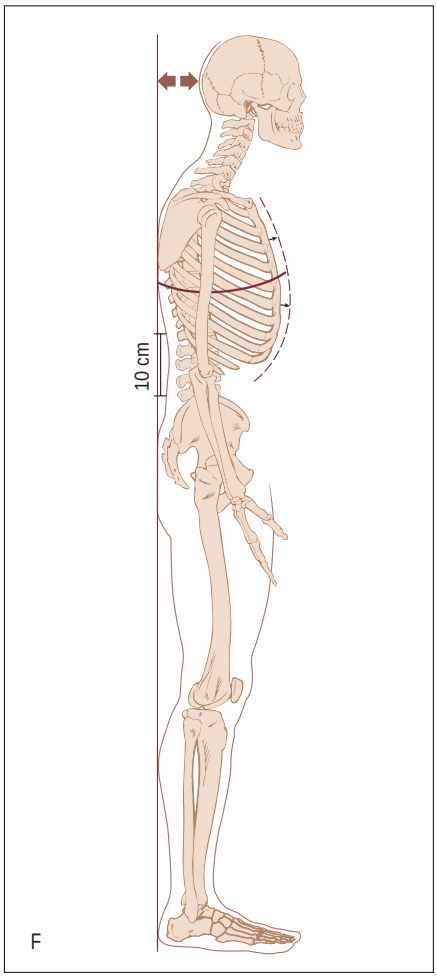

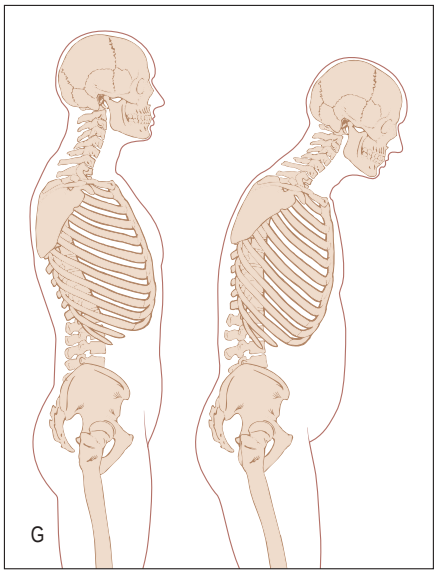

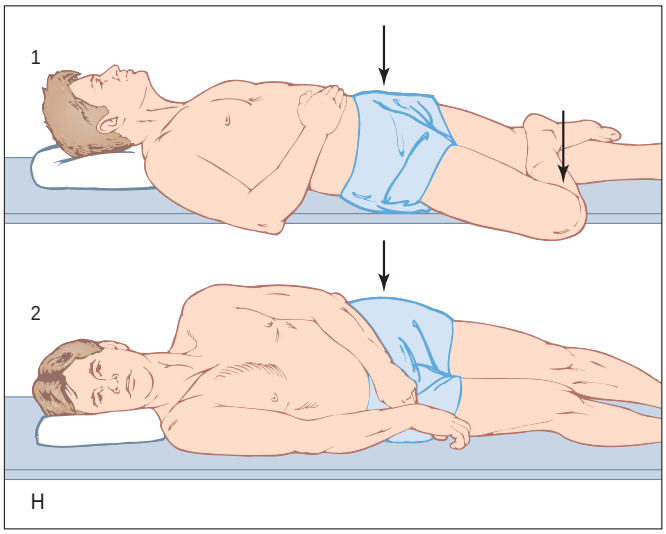

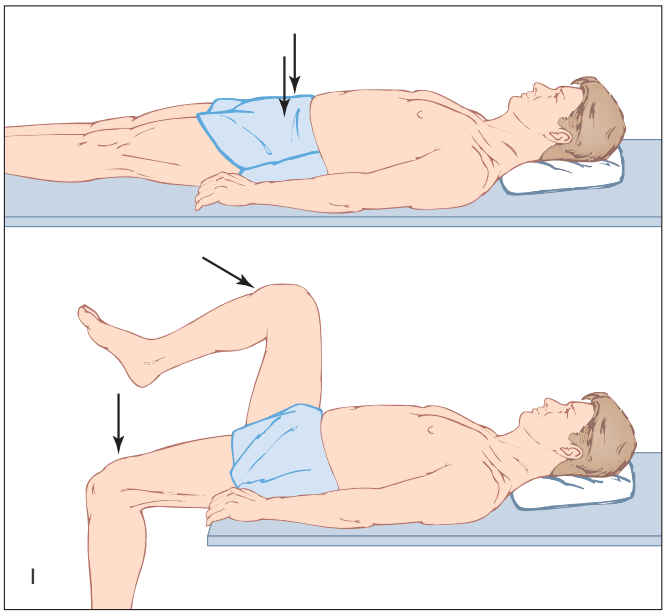

FIGURE 5-10. (*Continued*) **F,** Occiput to wall distance due to forwardly stooped deformity of cervical spine. Chest expansion is diminished due to costovertebral joint involvement. **G,** There is progressive kyphosis in advanced stages of disease. **H** and **I,** Test for eliciting sacroiliac pain by putting physical stress on the sacroiliac joints by application of downward pressure on the flexed knee, when the hip joint is flexed, abducted, and externally rotated; or by compression of the pelvis with the patient lying on one side (**H**). Two other procedures involve the application of direct pressure on anterior superior iliac spines, along with attempts to force them laterally apart, away from each other; and by forced flexion of one hip joint maximally toward the opposite shoulder, with hyperextension of the contralateral hip joint (**I**). (**A–C** *courtesy of* Heinz Baumberger.)

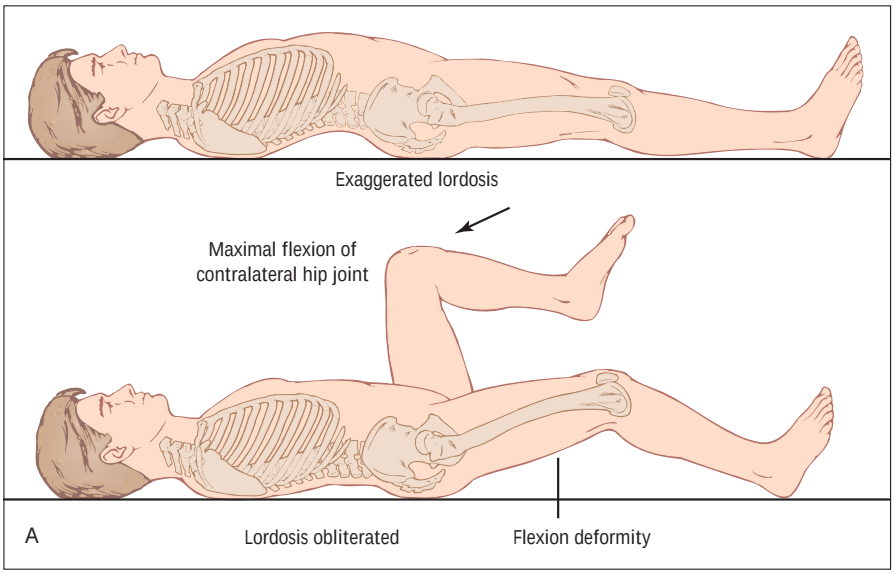

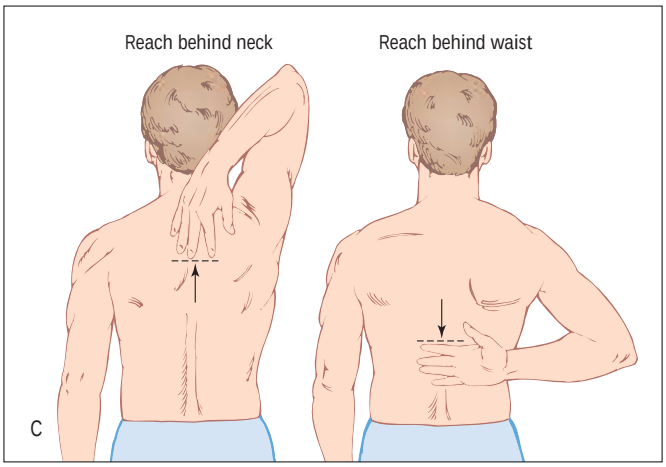

FIGURE 5-11. Hip and shoulder involvement. The reported frequency of hip joint involvement (**A,B**) varies from 17% to 36%; it is usually bilateral, insidious in onset, and potentially more crippling than involvement of any other joint of the extremities. It is relatively more common in patients with juvenile onset of ankylosing spondylitis. Flexion contractures of the hip are not uncommon at later stages of the disease and can be easily detected by having the patient lie on a very firm examining table and flexing one hip joint maximally to bring out the contracture in the contralateral hip joint. **C**, Shoulder joint involvement is generally relatively mild, but resulting limitation of motion can be easily detected by asking the patient to scratch his or her upper back.

Involvement of peripheral joints other than hips and shoulders in "primary" disease (*ie*, unassociated with psoriasis, inflammatory bowel disease, or reactive arthritis) is infrequent, rarely persistent or erosive, and tends to resolve without any residual joint deformity. Intermittent knee effusions may occasionally be the presenting manifestation of juvenile ankylosing spondylitis. Ten percent of the patients may show episodes of temporomandibular joint inflammation, which can result in limitation of jaw motion in some patients.

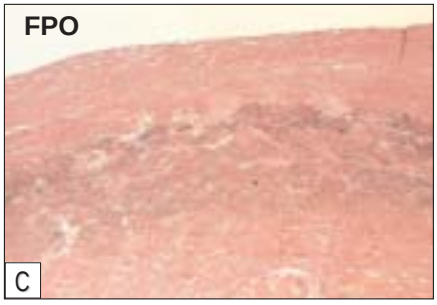

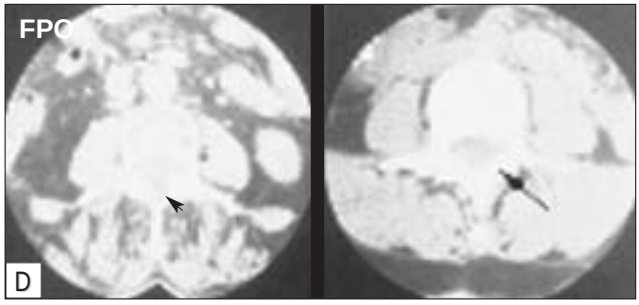

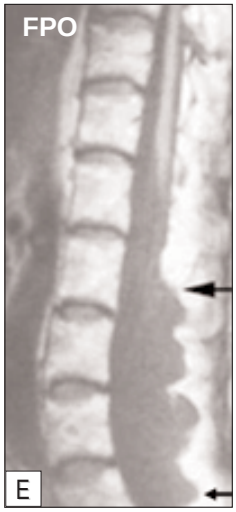

FIGURE 5-12. A, Uveitis. Acute anterior uveitis occurs in 25% to 30% of patients at some time in the course of their disease and is relatively more common among B27-positive than B27-negative patients [24,25,75,76]. The acute inflammation is typically unilateral, but it can recur in either eye. The patient presents with unilateral left ocular pain, redness, lacrimation, and photophobia evolving over a few days, which results in blurred vision owing to accumulation of inflammatory cells in the anterior chamber and abnormal accommodation of the ciliary muscles secondary to inflammation. There is circumcorneal congestion, and on slit-lamp examination, increased numbers of white blood cells are seen in the aqueous humor of the inflamed eye.

The other extra-articular manifestations are relatively uncommon and can include aortitis (**B,C**) (leading to slowly progressive aortic valve incompetency and conduction abnormalities, sometimes requiring a pacemaker) and myocardial diastolic dysfunction [2,26,78]. Apical pulmonary fibrosis (fibrocystic disease) is a rare complication of ankylosing spondylitis. Another rare complication is cauda equina syndrome (**D,E**). **D,** CT scan (*left*) showing erosions of the lamina of the fourth vertebra caused by arachnoid diverticula characteristic of cauda equina syndrome in ankylosing spondylitis (*arrowhead*). The CT scan on the *right* is at the same level in normal control. **E,** Lateral spinal view T1-weighted sagittal image of arachnoid diverticulitis showing fluid-filled arachnoid diverticuli (*arrows*). (**C–E** *from* the American College of Rheumatology [83]; with permission.)

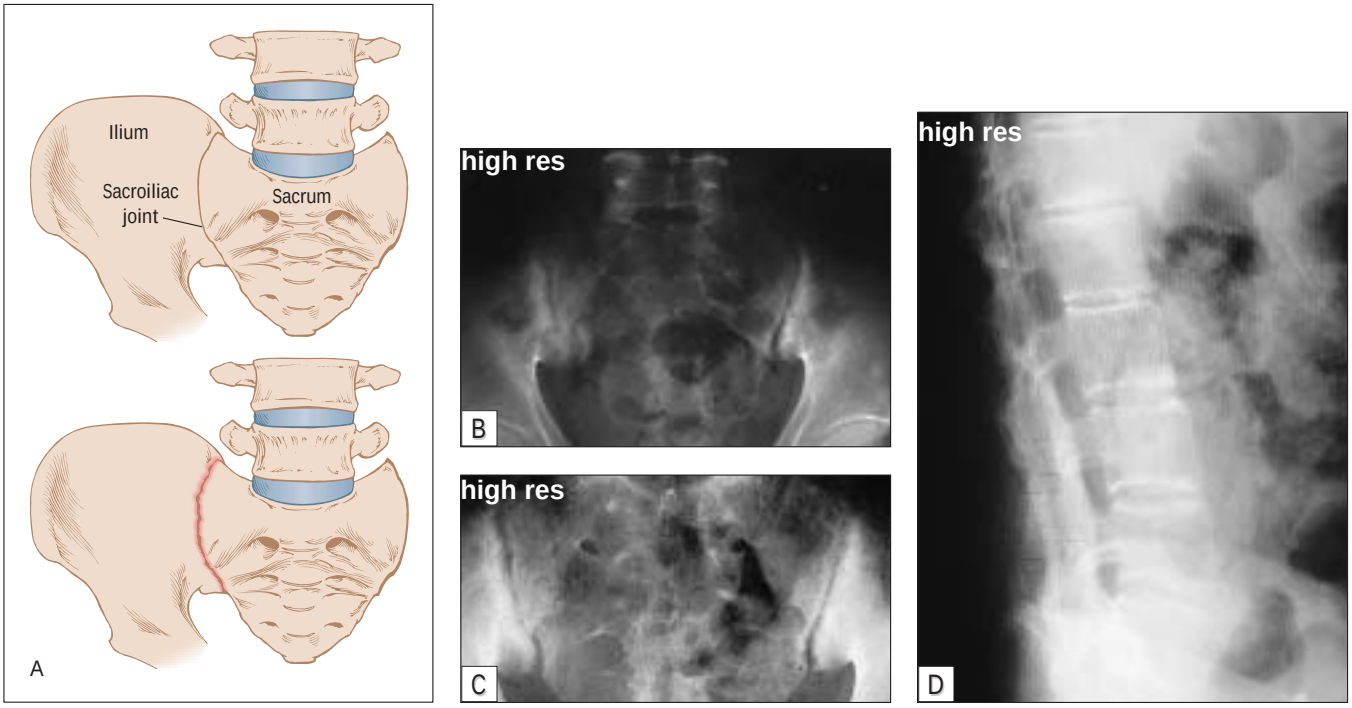

FIGURE 5-13. Demonstration of sacroiliitis. Schematic drawing (**A**) showing the location of the sacroiliac joint; the *red line* depicts sacroiliitis. The anteroposterior roentgenographic views in different patients (**B,C**) of the pelvis show bilateral sacroiliitis in ankylosing spondylitis (AS). There are erosions and blurring of the subchondral bone plate and reactive bone sclerosis that are more prominent on the iliac side of the joint. **D,** A lateral view of the lumbar spine of patient with AS shows reactive bony sclerosis of the corner ("shiny corners") of two adjacent vertebral bodies, and bone resorption of the anterior corners of the vertebral bodies that has resulted in vertebral "squaring." Spondylodiscitis is present at the vertebral disk between the T12 and L1 vertebrae.

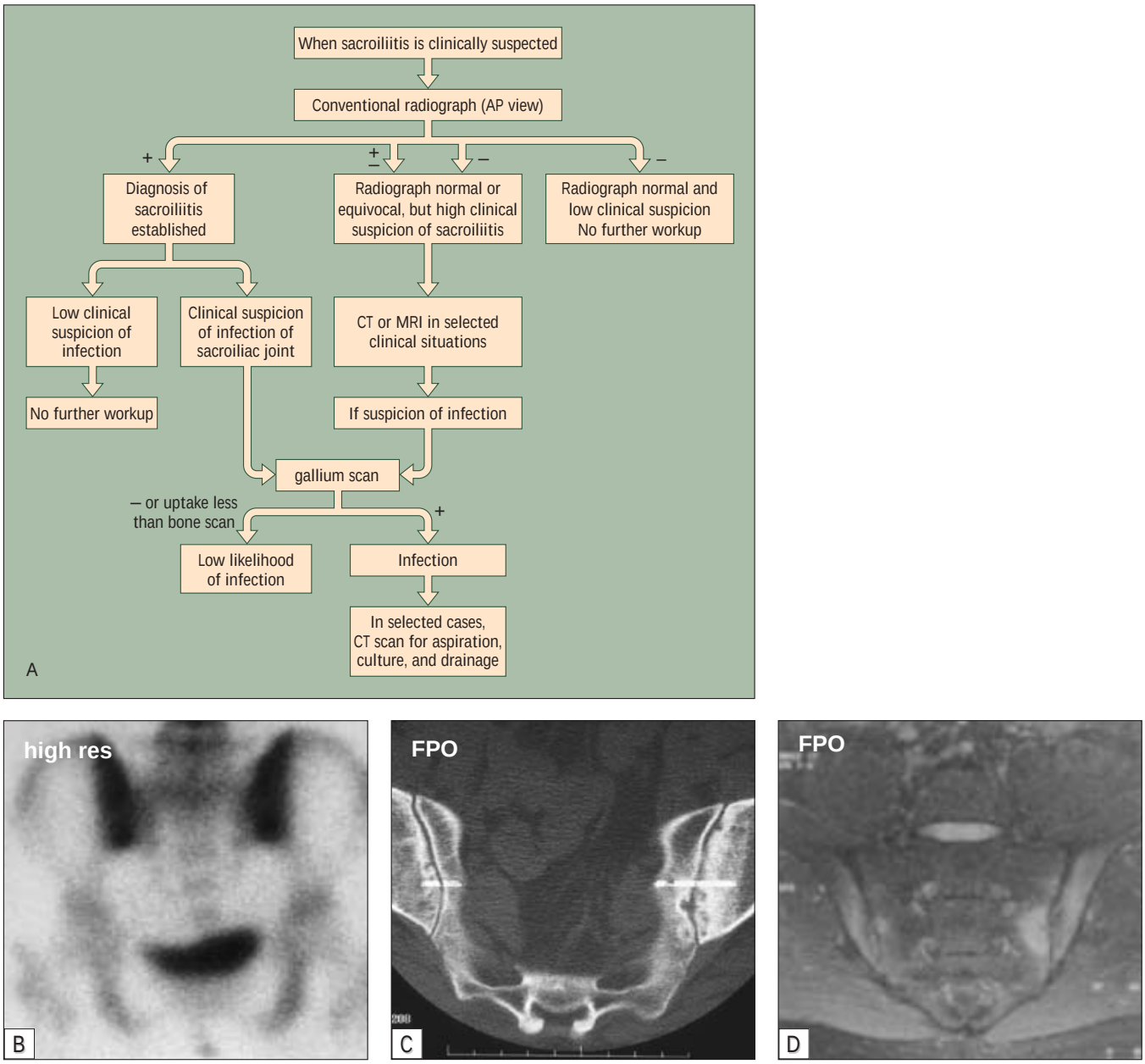

FIGURE 5-14. Imaging evaluation. **A,** Algorithm for characteristic evaluation of sacral ileitis due to spondyloarthropathies or infections. Ankylosing spondylitis may sometimes evolve over many years, but changes are usually present by the time the patient seeks medical attention. They are primarily seen in the axial skeleton, especially in the sacroiliac joints. Radiographic evidence of sacroiliitis is required for definitive diagnosis and is the most consistent finding; a simple anteroposterior (AP) roentgenogram is usually sufficient for its detection, and oblique views should not be requested. In patients with early disease in whom standard roentgenography of the sacroiliac joints may be normal or show equivocal changes, quantitative bone scintigraphy (**B**) may be too nonspecific to be useful [46,47]. CT is more sensitive but equally specific when compared with conventional roentgenography. **C,** CT image horizontal cut across the sacroiliac joints showing bilateral sacroiliitis. **D,** MRI gives excellent results and without radiation; it can show abnormalities of the periarticular bone marrow and subchondral bone, but at a greater cost. These two imaging modalities, however, are often not needed for the diagnosis of ankylosing spondylitis in most patients. MRI is very helpful in early detection of inflammation in sacroiliac joints and can predict the later occurrence of radiographically detectable sacroiliitis [4,84]. Short-T1 inversion recovery (STIR) fat saturation technique is useful for detecting bone marrow edema. Dynamic MRI using gadolinium detects inflammation. **B**,**C**, and **D** represent different patients. (*From* Khan [40]; with permission.)

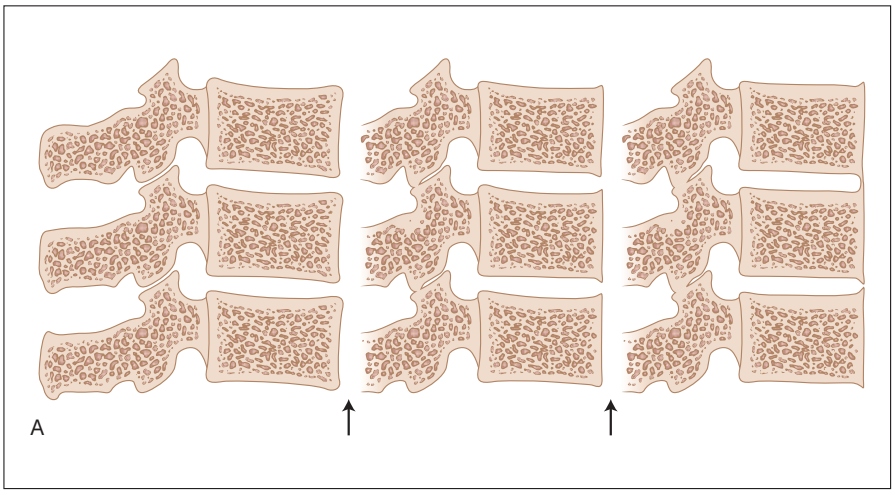

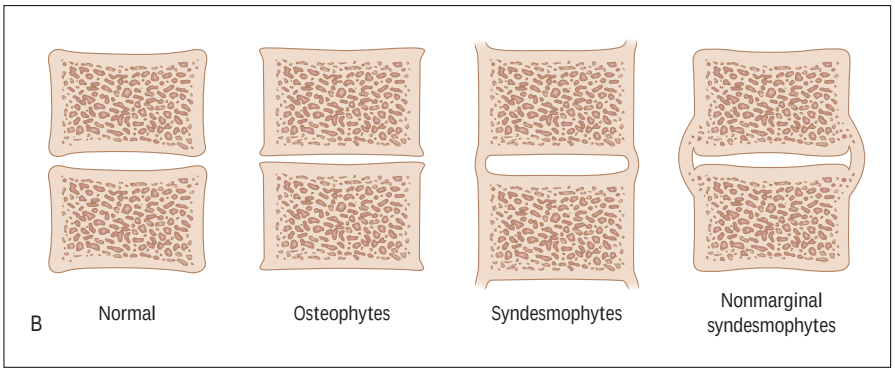

FIGURE 5-15. **A** and **B,** Schematic drawings of lumbar spine, lateral view (**A**) and antero-posterior view (**B**). The inflammation of the superficial layers of the anulus fibrosus and at their sites of attachment to the corners of the vertebral bodies results in reactive bony sclerosis ("shiny corners") and subsequent bone resorption (erosions). Ultimately, this leads to "squaring" of the vertebral bodies (*arrows*; best visualized on lateral radiography of the spine) (*see* Fig 5-13D) and a gradual formation of intervertebral bony "bridgings" called syndesmophytes (**C**). There are often concomitant inflammatory changes in the apophyseal joints that may lead to ankylosis, and ossification of the interspinous ligaments may also occur (**D**). There can be a complete fusion of the vertebral column ("bamboo spine") in patients with severe ankylosing spondylitis of long duration. Spinal osteoporosis, although usually seen in patients with long-standing ankylosing spondylitis, can sometimes develop in a relatively early stage of the disease. Some patients can develop severe kyphosis (**E**).
(**C** *from* Berens [85]; with permission.)

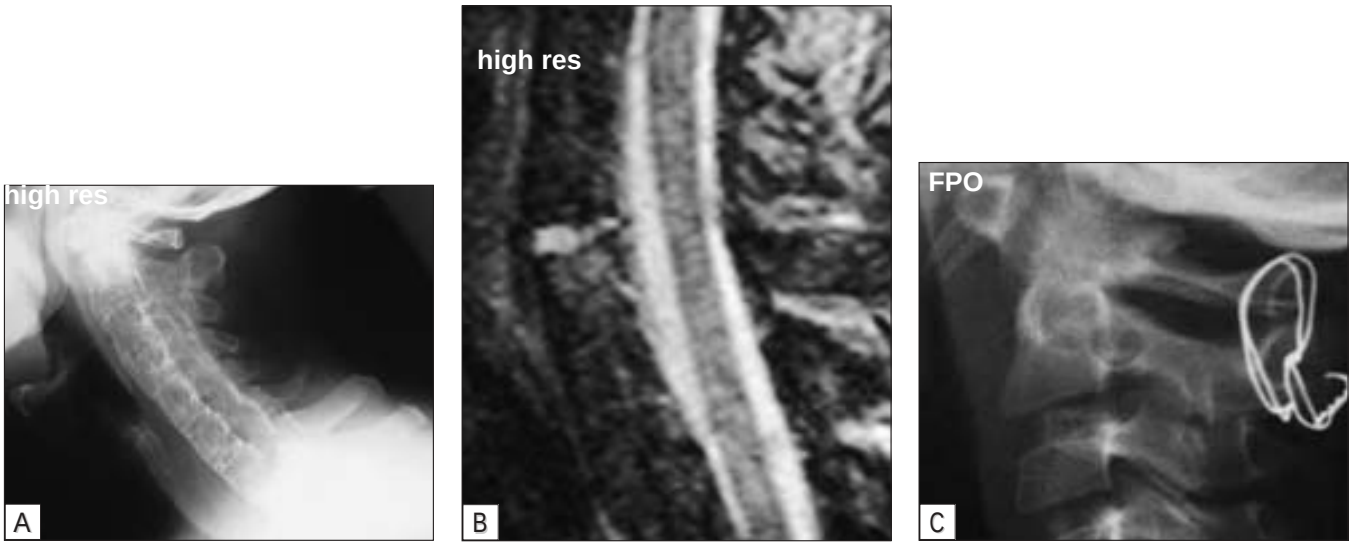

FIGURE 5-16. "Bamboo spine." **A**, This lateral view of the cervical spine shows a rigid and forward-stooping cervical spine of a patient with severe ankylosing spondylitis for more than 35 years. The spine is completely ankylosed ("bamboo spine") due to syndesmophytes and fused facet (apophyseal) joints. Spinal osteoporosis is also present. Such patients are prone to spinal fracture. In fact, this patient had sustained a lower cervical spine fracture that day and it could not be visualized on this radiograph. However, it was easily detected on an MRI scan (**B**). **C,** Spontaneous atlantoaxial subluxation: this radiograph (lateral view) shows incomplete reduction of the subluxation after surgery.



E. IMAGING EVALUATION FOR PSEUDOARTHROSIS

Clinical evidence of cord compression

Present	Absent
MRI	Spine radiography (including flexion view)
⊖	⊕
Bone scan	Perform CT or sagittal tomography
If positive, perform CT or sagittal tomography	

FIGURE 5-17. Spinal fracture. **A** through **D**, Spinal fracture can follow a relatively minor trauma in patients with long-standing severe ankylosing spondylitis because the ankylosed and osteoporotic spine is prone to fractures, usually occurring in the lower cervical spine. Quadriplegia is the most dreaded complication because of its high mortality rate. Isolated or multiple vertebral compression fractures may also occur. The pain associated with spinal fractures may be overlooked or wrongly attributed to exacerbation of the spondylitic process and could lead to diskovertebral destruction (spinal pseudoarthrosis) [79–81,84,86]. **A**, Bone scan showing lower cervical spine fracture. **B** and **C**, Firm bracing with the use of a halo-vest is needed to allow the cervical spinal fracture to heal. **D**, Skeleton of spondylitic patient showing lumbar fracture and resultant pseudoarthrosis. Imaging evaluation is necessary for evaluation of pseudoarthrosis (**E**).

The best early clinical clues to spinal fracture may be a history of an acute or unexplained episode of back pain that is aggravated by movement, even in the absence of obvious physical trauma. It may sometimes be associated with localized spinal tenderness. Some patients may develop aseptic spondylodiskitis, mostly in the midthoracic spine. It is usually asymptomatic and without any physical trauma or infection and is relatively more common in the patients whose spondylitis also involves the cervical spine.

A. SPINAL RADIOLOGIC FEATURES OF ANKYLOSING SPONDYLITIS

- Vertebral squaring
- Osteopenia
- Spondylitis anterior (Romanus lesion)
- Nondestructive marginal vertebral sclerosis (shiny corner)
- Spondylodiscitis (Anderson lesion)
- Joint capsule and ligament ossification
- Syndesmophytes
- Bamboo spine
- Vertebral fractures

FIGURE 5-18. A, Radiologic features of ankylosing spondylitis. **B,** Radiograph of the lumbar spine, lateral view, showing Anderson's lesion of fourth lumbar vertebra in a patient with relatively early stage ankylosing spondylitis. Osteopenia is also present. **C,** Sagittal T1-weighted MRI of the same patient shows multisegmental involvement of the vertebral bodies (seen as dark areas) that was not visible on the plain radiograph. With STIR fat-suppression sequence, these dark punched-out areas of the vertebral bodies would be seen as white areas. Use of gadolinium can further help to demonstrate this inflammation-related bone edema. T1 turbo spin-echo MRI also can detect ankylosis. (**B** and **C,** *courtesy of* J. Braun.)

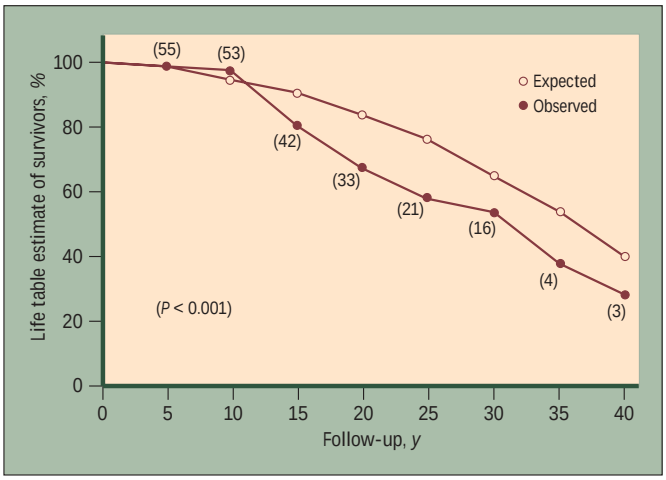

FIGURE 5-19. Survival curve. Long-term survival studies indicate that severe ankylosing spondylitis may result in slight shortening of the lifespan beginning 15 years after diagnosis [87,88]. Because the average age of diagnosis is 30 to 32 years (mean age of onset is 25, and 5- to 7-year delay in diagnosis), the trend toward a slight reduction in survival starts at about age 50. Life-table estimates of percent survival as compared with what is expected are shown; the numbers in parentheses indicate the patient sample size followed in an arthritis outpatient clinic. Three patients had a maximum follow-up of up to 40 years. Because most patients with ankylosing spondylitis do not suffer from very severe disease, these data do not apply to such patients, who have a normal lifespan.

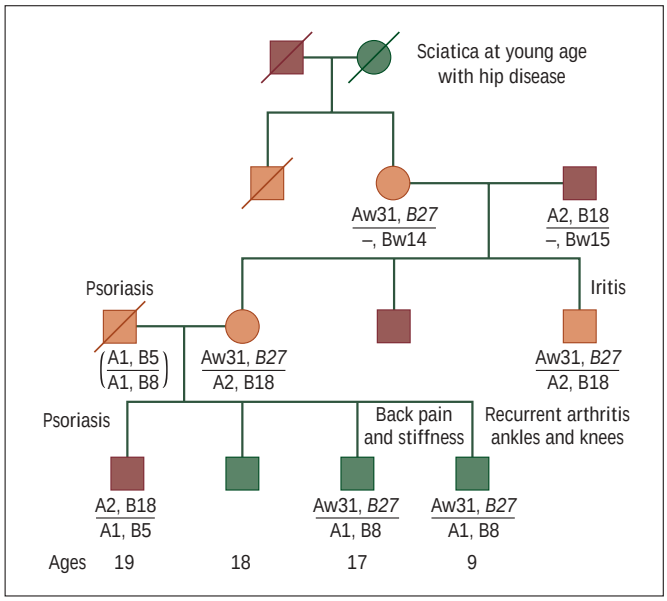

FIGURE 5-20. Family pedigree. This family shows marked familial aggregation of spondyloarthropathies. There is also presence of psoriasis in this family. Other families may show a presence of Crohn's disease or ulcerative colitis. Patients with psoriasis or inflammatory bowel disease are more likely to later develop ankylosing spondylitis than the rest of the population without these diseases, and the reverse is also true, *ie,* patients with ankylosing spondylitis are more often found to have Crohn's disease, ulcerative colitis, or psoriasis. Ileocolonoscopic studies have disclosed the presence of subclinical bowel inflammation in a large number of patients with spondyloarthropathies who had no other evidence of inflammatory bowel disease [68–70]. Individuals affected with ankylosing spondylitis are shown as *orange squares* (males) and *circles* (females). *Green squares and circles* indicate related spondyloarthropathies, and *red color* indicates unaffected individuals. Segregation of HLA-A and –B haplotypes is also shown.

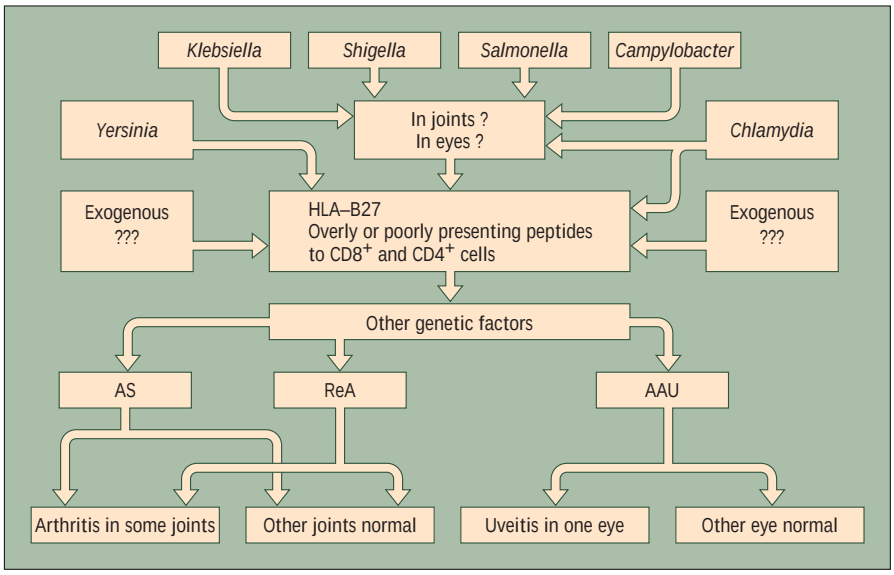

FIGURE 5-21. HLA-B27 as a common pathogenetic pathway. Feltkamp [89] suggested a scheme with HLA-B27 acting as a common pathogenic pathway between several exogenous (environmental) and genetic factors and the phenotypic expression of spondyloarthropathies. Recent findings indicate that HLA-B27 mediates not only CD8+ T-cell responses but can also trigger CD4+ T-cell responses in vitro and in vivo [93]. HLA-B27-associated disease risk is enhanced by the presence of other genetic factors that play an important role in disease predisposition [10–16,90–93]. One of the reasons for the unilateral episode of acute anterior uveitis (AAU) and the often asymmetric peripheral arthritis of reactive arthritis (ReA) may be the randomness of the arrival of the exogenous antigenic inflammatory triggers at these sites. AS—ankylosing spondylitis. (*Adapted from* Feltkamp [89].)

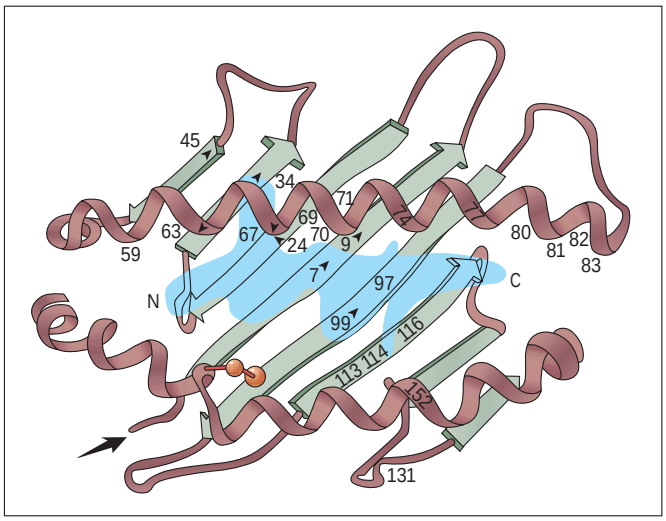

FIGURE 5-22. Schematic ribbon diagram of the antigen-binding cleft of the HLA-B*2705 molecule, the most common subtype of HLA-B27 in caucasoid populations. A nonameric (nine amino acid–long) antigenic peptide is shown anchored (bound) in the antigen-binding cleft of the molecule. The view is from above, as seen from the viewpoint of a T-cell receptor. The letters *N* and *C* indicate the amino (N) and carboxy (C) termini of the bound peptide. The *arrow* indicates the amino-terminus of the alpha (heavy) chain of the HLA-B27 molecule. The floor of the antigen-binding cleft is formed by the beta strands (*broad arrows* pointing away from the amino-terminus), and the margins are formed by alpha-helices shown as *helical ribbons*. The top alpha helix and the four beta strands to the left are from the alpha-1 domain of the heavy chain, and the bottom alpha helix and the four beta strands to the right are from the alpha-2 domain. The disulfide bond is shown as two *connecting spheres*. Not marked are the six side pockets (assigned the letters A, B, C, D, E, and F) on the surface of the antigen-binding cleft. Pockets A and F are highly conserved deep pockets at the two ends of the antigen-binding cleft. The residues that form pocket B are marked by *black arrowheads* (at positions 7, 9, 24, 34, 45, 63, 67, and 99). The side chain of the second amino acid (arginine) of the bound peptide is shown anchored into pocket B. There are at least 25 subtypes of HLA-B27, from B*2701 to B*2725 [15]. The various subtypes of HLA-B27 show different ethnic distributions, and some of them may also show differences in disease association. For example, the common subtypes in various world populations—B*2705, B*2702, and B*2704—are clearly associated with ankylosing spondylitis, whereas B*2709 in Sardinian Italians and B*2706 in Southeast Asians seem to lack such an association [10,36]. It is difficult to assess the disease association of the relatively uncommon subtypes at the population level. The two subtypes of HLA-B27 that are not associated with ankylosing spondylitis, that is, B*2706 and B*2709, differ from the other subtypes at residues 114 and 116, primarily affecting the conformation of pocket C/F. (*Adapted from* Khan [90].)

COMPARISON OF CLINICAL FEATURES OF B27-POSITIVE AND B27-NEGATIVE PATIENTS WITH PRIMARY ANKYLOSING SPONDYLITIS

	B27(+) AS	B27(-) AS
Racial group	All races	Increased in non-whites
Age of onset	15–40 y	18–50 y
Family history	++	–
Acute anterior uveitis	++	+
Skeletal manifestations	++	++

FIGURE 5-23. Clinical features of HLA-B27–positive and HLA-B27–negative patients with ankylosing spondylitis (AS) [76].

A. HLA-B27 FREQUENCY IN PATIENTS AND NORMAL CONTROLS

Group	Whites		Blacks	
	n	B27(+), %	*n*	B27(+), %
Control	485	8	60	2
Ankylosing spondylitis	140	92	36	49
Reactive arthritis (Reiter's syndrome)	54	72	20	40

B. PERCENT OF B27-POSITIVE PATIENTS AND NORMAL CONTROLS BY VARIOUS POPULATIONS

	Ankylosing Spondylitis		Normal Controls	
Populations	Patients, n	B27 positive, %	Controls, n	B27 positive, %
Caucasoid				
Whites	2022	79–100	16,162	4–13
Indians and Pakistanis	130	83–100	456	2–8
Iranians	25	92	400	3
Arabs	32	81	355	3
Jews	31	81	456	3
Mongoloid				
Chinese				
Mainland China	196	89–91	726	2–7
Hong Kong	77	99	102	4
Taiwan	76	95	297	9
Singapore	29	97	238	7
Japanese	72	82	208	< 1
Filipino	17	94	529	5–8
Thai	71	86	138	5
North American Indians				
Haida	17	100	222	50
Navajo	5	80	100	36
Bella Colla	3	100	129	25
Pima	14	100	400	18
Zuni			158	13
Hopi			100	9
Mestizo	239	69–81	1404	3–7
South American Indians			440	0
Negroid				
African blacks				
Central Africans				
Congo and Zambia			259	0
West Africans				
Mali			82	9.7
Gambia			702	2.6
South Africans				
Zimbabwe	7	0		< 0.01
South Africa	9	22	798	1
American blacks	67	57	1330	2–4

**Eskimos are not listed in the table; they have 25%–37% frequency of B27, and virtually all patients with ankylosing spondylitis are B27-positive [7]. Frequency of B27 is 9% in Indonesia and more than 25% in an isolated community in Papua New Guinea.*

FIGURE 5-24. Laboratory evaluation. There are no "diagnostic" or pathognomonic laboratory tests. An elevated erythrocyte sedimentation rate and C-reactive protein are observed in approximately 75% of patients, and a mild-to-moderate elevation of serum immunoglobulin A concentration is also commonly present. There is no association with rheumatoid factor and antinuclear antibodies, and the synovial fluid and synovial biopsy do not show markedly distinctive features as compared with other inflammatory arthropathies. Most patients with ankylosing spondylitis (AS) can be readily diagnosed clinically on the basis of history, physical examination, and roentgenographic findings. **A**, The prevalence of HLA-B27 among normal controls and patients studied by the author in Cleveland, Ohio. The association of HLA-B27 with spondyloarthropathies is stronger among whites than blacks. **B**, The prevalence of HLA-B27 and its disease association varies among many racial and ethnic groups [7]. **C**, The presence or absence of HLA-B27 cannot definitely establish or exclude the diagnosis because HLA-B27 as a test for the disease is neither 100% specific nor 100% sensitive.

(*Continued on next page*)

C. IMPORTANT ASPECTS OF THE HLA-B27 TEST

- It is not a "routine" or "diagnostic" or "confirmatory" test
- Most patients with AS can be diagnosed clinically and do not need this test
- It cannot be used as a screening test for AS in the general population
- The sensitivity and specificity of the test depend on the racial and ethnic background of the patient
- The clinical usefulness of the test, like any other "imperfect" test, depends on the clinical setting in which it is performed, and requires Bayesian analysis to correctly interpret the clinical meaning of positive or negative test results
- The test can, in a similar manner, also be used as an aid to support the diagnosis of other B27-associated spondyloarthropathies besides AS
- The test does not help distinguish AS from other B27-associated spondyloarthropathies

FIGURE 5-24. (*Continued*) The prevalence of HLA-B27 in the general population (from which is derived the specificity of the HLA-B27 test) and the strength of its disease association (*ie*, the sensitivity of the test) also vary markedly among many ethnic and racial groups [47,78]. HLA-B27 typing cannot be used as a "routine," "diagnostic," "confirmatory," or "screening" test for AS in patients with back pain or arthritis. A physician who understands the principles of probability reasoning (Bayesian analysis) can, however, use the test appropriately to support a positive diagnosis in cases that may less clear (primarily owing to slow evolution of diagnostic radiographic sacroiliitis) [4,89]. HLA-B27 is associated with all the spondyloarthropathies, and differentiation among these diseases is based on the clinical findings summarized in **D**. (**D** *adapted from* Arnett *et al*. [92] and Khan [40].)

D. CLINICAL FEATURES OF VARIOUS SPONDYLOARTHROPATHIES

Characteristic	Ankylosing Spondylitis	Reactive Arthritis (Reiter's Syndrome)	Juvenile Spondyloarthropathy	Psoriatic Arthropathy*	Enteropathic Arthropathy†
Usual age at onset	Young adult age < 40	Young to middle-age adult	Childhood onset, ages 8–18	Young to middle-age adult	Young to middle-age adult
Sex ratio	3× more common in males	Predominantly males	Predominantly males	Equally distributed	Equally distributed
Usual type of onset	Gradual	Acute	Variable	Variable	Gradual
Sacroiliitis or spondylitis	Virtually 100%	< 50%	< 50%	~ 20%	< 20%
Symmetry of sacroiliitis	Symmetric	Asymmetric	Variable	Asymmetric	Symmetric
Peripheral joint involvement	~ 25%	~ 90%	~ 90%	~ 95%	15%–20%
HLA-B27 (in whites)	> 90%	~ 75%	~ 85%	< 50%‡	~ 50%
Eye involvement§	25%–30%	~ 50%	~ 20%	~ 20%	~ 15%
Cardiac involvement	1%–4%	5%–10%	Rare	Rare	Rare
Skin, mucosal, or nail involvement	None	~ 40%	Uncommon	Virtually 100%	Uncommon

**About 5%–7% of patients with psoriasis develop arthritis, and psoriatic spondylitis accounts for about 5% of all patients with psoriatic arthritis.*
†Associated with chronic inflammatory bowel disease.
‡B27 prevalence is higher in those with spondylitis or sacroiliitis.
§Predominantly conjunctivitis in reactive and psoriatic arthritis, and acute anterior uveitis in the other disorders listed above.

Early Diagnosis of Ankylosing Spondylitis and Axial Spondyloarthritis

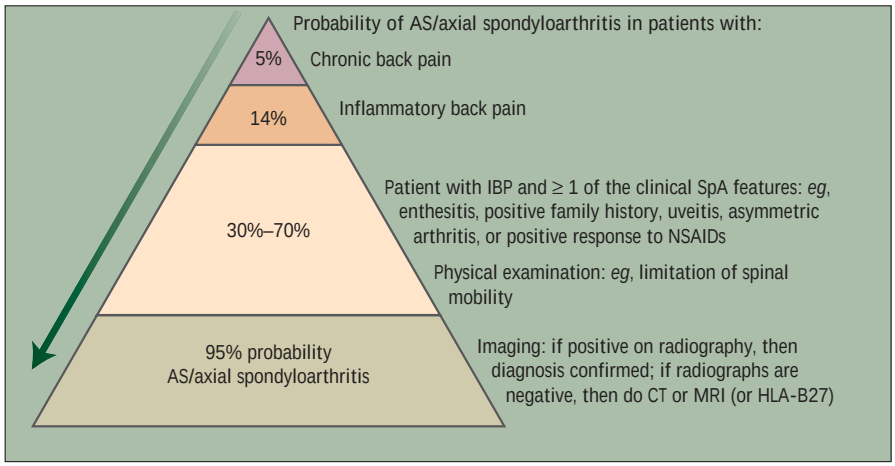

FIGURE 5-25. Suggested algorithm to help make an early diagnosis of ankylosing spondylitis (AS)/axial spondyloarthritis (SpA). IBP—inflammatory back pain; NSAIDs—nonsteroidal anti-inflammatory drugs. (*Adapted from* Rudwaleit *et al*. [4] and Khan [40].)

SALIENT PRINCIPLES FOR MANAGEMENT OF ANKYLOSING SPONDYLITIS

No cure but most patients can be well managed with NSAIDs and regular exercise program; for those with more severe disease, preliminary results indicate significant efficacy of anti-TNF therapy
A concerned (primary) physician providing continuity of care; consultation as needed by a rheumatologist, ophthalmologist, orthopedist, and others
Education of the patient about the disease to help increase compliance
Importance of daily exercises to preserve good posture and minimize limitation of chest expansion; swimming is the best exercise; appropriate sports and recreations; sleeping on firm mattress; avoiding pillows under the head, if possible; avoidance of smoking; and prevention of spinal trauma
Supportive measures and counseling with regard to social, sexual, and vocational aspects; importance of patient support groups
Family counseling; thorough family history; physical examination of the relatives may disclose remarkable disease aggregation and many undiagnosed or misdiagnosed affected relatives in some families
Surgical measures: arthroplasty, correction of deformity, and others
Early diagnosis is important, as is the early recognition and treatment of extraskeletal manifestations, such as acute anterior uveitis (iritis), and of the associated disease or complications
Anti-TNF therapy with infliximab is very effective for severe Crohn's disease and also benefits any associated inflammatory arthritis [95]

FIGURE 5-26. Management of ankylosing spondylitis (AS). Many patients with AS can be well managed with nonsteroidal anti-inflammatory drugs (NSAIDs) along with physiotherapy and a life-long regular exercise program [1,3,88]. There is currently no known method to cure or prevent the disease, and there is no special diet or any specific food that has a role in its initiation or exacerbation. Aspirin seldom provides an adequate therapeutic response, but other NSAIDs are more helpful and should be used in full therapeutic anti-inflammatory doses during active phases of the disease [1,3,88]. The patients should be informed about this because otherwise they may use the drugs occasionally and for their analgesic effect only. The responses by patients differ, as do the side effects, and it is worthwhile to search out the best alternative NSAID that works for each individual.

When the disease is not being adequately controlled by NSAIDs, the so-called disease-modifying antirheumatic drugs (DMARDs) used in the treatment of rheumatoid arthritis are not very effective; sulfasalazine may be moderately effective for peripheral arthritis, but has no significant beneficial effect on the typical axial disease, although its possible efficacy in early axial disease has not been studied [91,96,97]. Because of its efficacy in inflammatory bowel disease (IBD), sulfasalazine may be especially useful for AS associated with IBD. Some AS patients with peripheral joint involvement unresponsive to NSAIDs and sulfasalazine have responded to oral methotrexate therapy. However, a randomized double-blind, placebo-controlled study of 30 patients with severe AS has demonstrated no significant benefits in the group receiving oral methotrexate (10 mg weekly) for 24 weeks versus placebo, even in the subgroup with peripheral arthritis [95]. Oral corticosteroids have no therapeutic value in the long-term management of the musculoskeletal aspects of this disease because of their serious side effects, and the do not halt disease progression. Persistent synovitis may respond to a local corticosteroid injection, and uncontrolled studies of corticosteroid injection into the sacroiliac joints show that it may be helpful but the benefit lasts only a few months. Patients with severe spondyloarthropathies who were unresponsive to conventional therapies have now been treated with anti–tumor necrosis factor (TNF)-a therapy (ie, infliximab and etanercept), with rapid improvement of peripheral arthritis as well as axial symptoms and signs, including enthesitis as detected by MRI [94,94,98–104]. TNF blockers are also very effective in the treatment of psoriasis and psoriatic arthritis resistant to conventional therapy.

Infliximab, but not etanercept, is also effective in Crohn's disease [95]. There is a case report of anti-TNF treatment for nephrotic syndrome in a patient with juvenile IBD-associated spondyloarthropathy complicated with amyloidosis and glomerulonephritis [104]. Consensus statements are being developed to establish criteria to be used in deciding the patient with spondyloarthropathy that may need this treatment and how to evaluate the therapeutic response [105,106]. The high cost of these new biologic agents and their major untoward effects, including opportunistic infections, reactivation of infections such as tuberculosis and histoplasmosis, and as yet unknown other possible side effects of long-term therapy, are, at present, the major deterrents. Experimental drugs under study for possible therapeutic effect in AS include pamidronate, a biphosphonate that needs intravenous infusion, and thalidomide [107–110]. However, no controlled studies have been reported.

The patient should walk erect, keeping the spine as straight as possible, and sleep on a firm mattress using as thin a pillow as possible. Physical activity that places prolonged strain on the back muscles such as prolonged stopping or bending, should be avoided. Self-help education, counseling, and health education for self-management are helpful in enhancing compliance with the recommended therapy [111–114]. Patient support groups enlist enthusiastic patient cooperation and provide information about the disease and advice about life and health insurance, jobs, working environment, wide-view mirrors, and other useful items [114]. Splints, braces, and corsets are generally not helpful and are not advised. Pregnancy does not usually affect the disease symptoms, and fertility, course of pregnancy, and childbirth have been reported to be normal. Regular exercise is of fundamental importance in preventing or minimizing deformity. Spinal extensions exercises and deep-breathing exercises should be done routinely once or twice daily, and smoking should be avoided [114]. Formal physical therapy is of value, especially in teaching the patient the proper posture, appropriate exercises, and recreational sports, and the need for maintaining the exercise program. Group exercise sessions that include hydrotherapy in warm water are helpful. Regular swimming is considered one of the best exercises for these patients. Some patients have difficulty driving their car because of the impaired neck mobility, and they may find special wide-view mirrors helpful.

Acute anterior uveitis requires prompt and vigorous treatment with dilation of the pupil and use of corticosteroid eye drops. The patient should be informed about the possibility of recurrence of acute iritis. Systemic steroids or immunosuppresives may be needed for rare patients with severe refractory uveitis, and recent data suggest that anti-TNF therapy is dramatically effective for these patients. Total hip arthroplasty gives very good results and prevents partial or total disability from severe hip disease. Vertebral wedge osteotomy may be needed for correction of severe kyphosis in some patients, although it carries a relatively high risk of paraplegia. Cardiac complications may require aortic valve replacement or pacemaker implantation. Apical pulmonary fibrosis and cavitation are not easy to manage; surgical resection may be rarely required.

FIGURE 5-27. Effects of infliximab therapy. The spinal MRI on the left part of the figure (lateral view) shows sites of enthesitis (*arrows*) that resolved (right part of figure) after infliximab therapy. The MRI on the right was taken after 1 year of treatment with infliximab. (*Courtesy of* J. Braun.)

Reactive Arthritis

Clinical Presentation

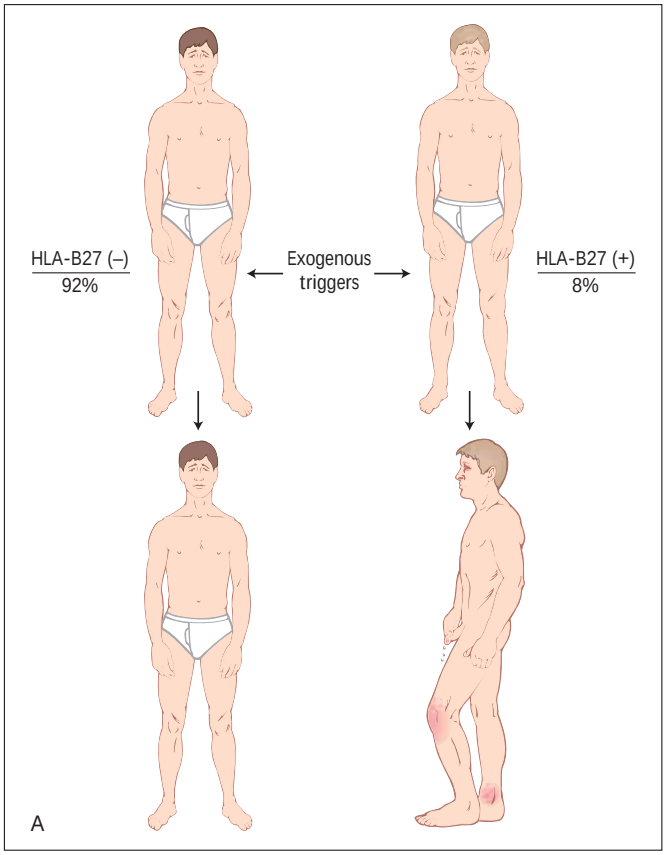

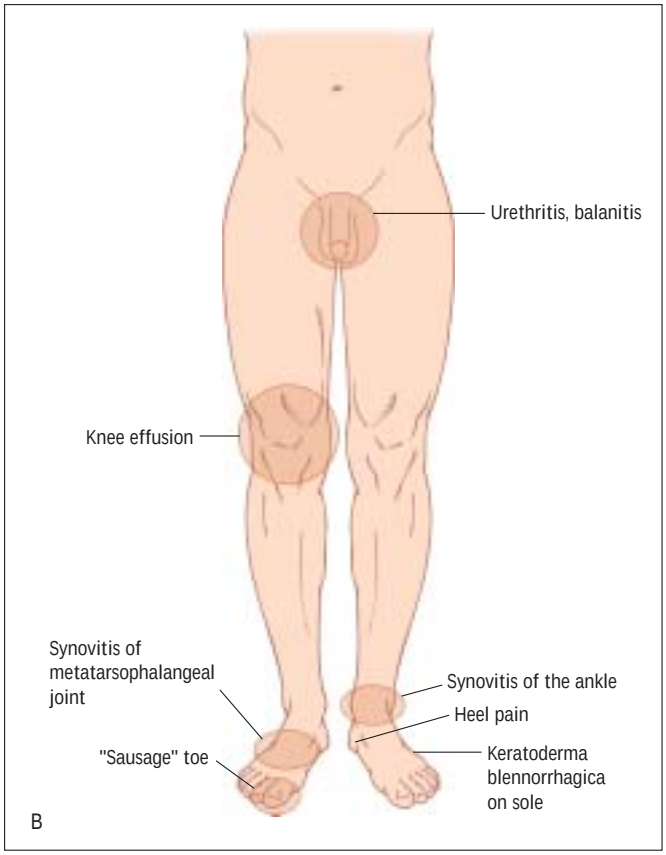

FIGURE 5-28. Presentation. **A–C,** Reactive arthritis, or Reiter's syndrome, usually presents with acute oligoarticular arthritis, affecting more often the joints of the lower extremities.

(*Continued on next page*)

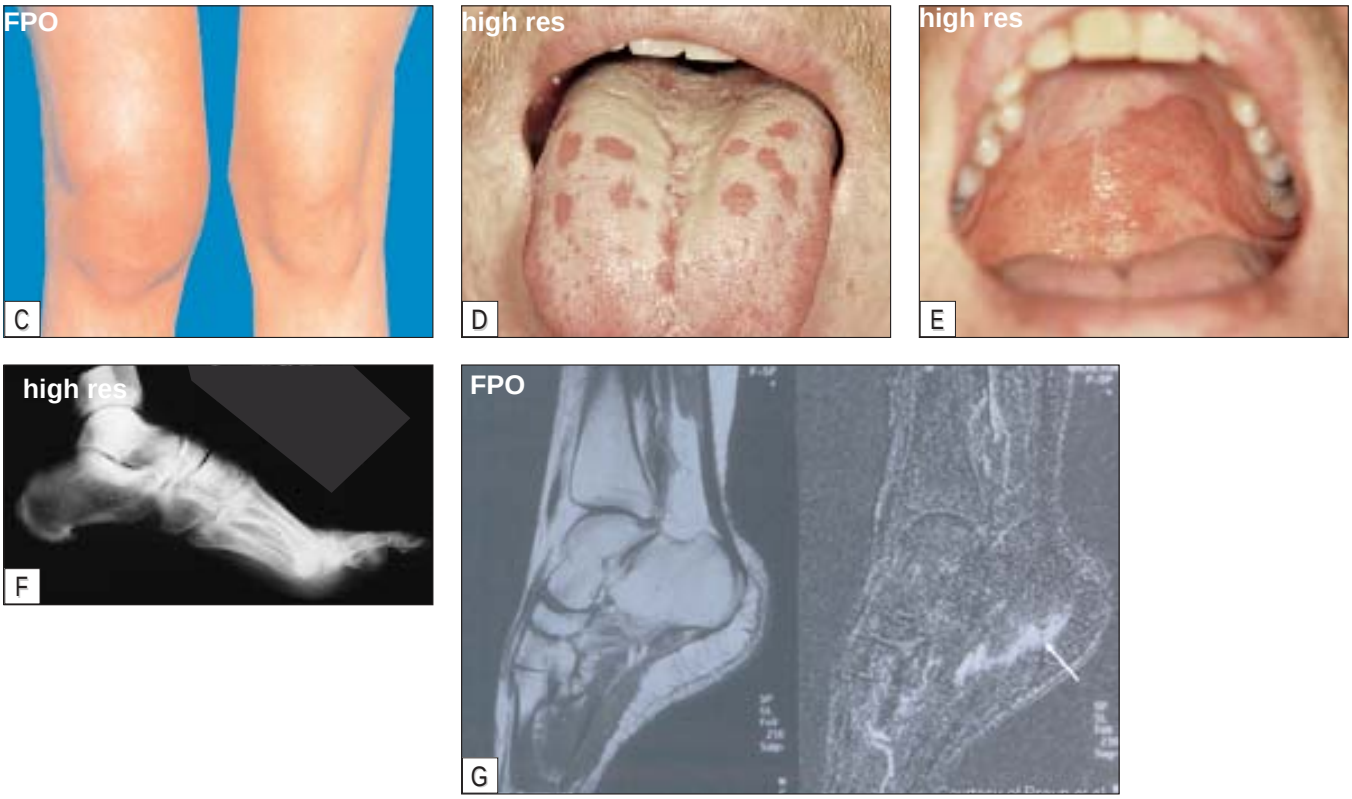

FIGURE 5-28. (*Continued*) HLA-B27 predisposes the person exposed to the exogenous triggering agent. HLA-B27–negative patients who are exposed to the agent are much less likely to develop reactive arthritis. The arthritis usually resolves in about 3 months but can have recurrences or become chronic.

The patient can show arthritis, diarrhea, balanitis or cervicitis, conjunctivitis, acute anterior uveitis, psoriasiform rashes (keratoderma, or pustular psoriasiform lesion on palms and soles), painless superficial mucosal ulcerations (**D, E**), onycholysis without pitting of the nails, diffuse swelling digits ("sausage" digits; *see* Fig. 28*C*), Achilles tendonitis, and plantar fasciitis (**F,G**) can result in erosions and periosteal "whiskering" at sites of attachment of the Achilles tendon and the plantar fascia. **G** shows presence of plantar fasciitis as detected by gadolinium-enhanced MRI (*left*), which is better demonstrated on subsection imaging (*right*). (**C** *courtesy of* Khan and Sieper [55] and **G** *from* Braun *et al.* [19]; with permission.)

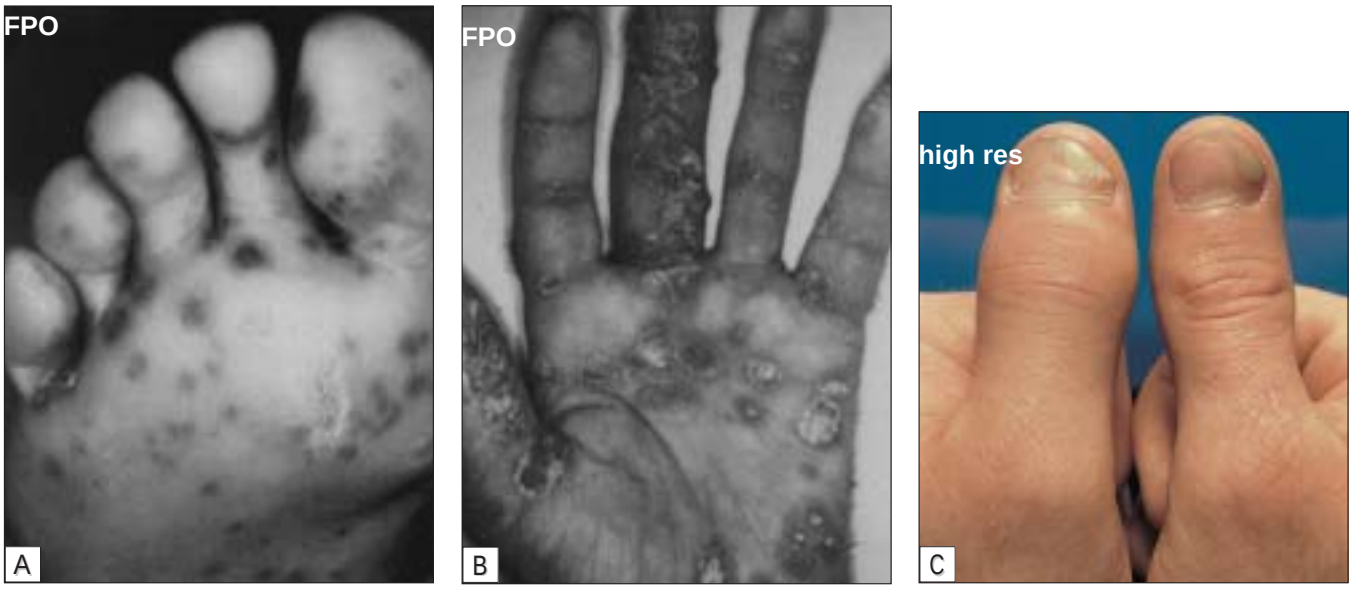

FIGURE 5-29. **A** and **B,** Palmar and plantar skin lesions of keratoderma blennorrhagica. **C**, The left thumb in a patient with reactive arthritis shows onycholysis of thumb nail and dactylitis ("sausage" digits). The nails show no pitting or ridging that occurs in psoriatic arthritis (*see* Fig. 33*F*). (**A** and **B** *from* Koopman [115]; **C** *from* Khan and Skosey [116]; with permission.)

FIGURE 5-30. Asymmetic sacroiliitis. Anteroposterior roentgenographic view of the pelvis shows bilateral but somewhat asymmetric sacroiliitis in a patient with reactive arthritis.

FIGURE 5-31. Chronic reactive arthritis. Anteroposterior roentgenographic view of the pelvis and lumbar spine in a patient with chronic reactive arthritis shows asymmetric nonmarginal syndesmophytes that originate a little distance away from the corners of the vertebrae, in contradistinction to the marginal syndesmophytes of ankylosing spondylitis. Patients with psoriatic spondyloarthropathy are also more likely to develop similar nonmarginal syndesmophytes. Involvement of sacroiliac joints (sacroiliitis) is frequently observed and often asymmetric. There are no erosive changes of the sacroiliac joints in the patient's radiograph shown, although the right-sided joint is slightly indistinct. Similar radiologic findings can also be observed in patients with psoriatic spondylitis. (*From* Mustafa and Khan [117]; with permission.)

A. BACTERIAL INFECTIONS THAT CAN TRIGGER HLA-B27–ASSOCIATED REACTIVE ARTHRITIS

Gastrointestinal infection
- Usual triggers
- *Shigella flexneri*
- *Salmonella enteritidis* and *Salmonella typhimurium*
- *Yersinia enterocolitica* and *Yersinia pseudotuberculosis*
- *Campylobacter jejuni*
- Unusual triggers
- *Shigella sonnei* and *Shigella dysenteriae*
- *Salmonella paratyphi*
- Bacillus Calmette-Guérin
- *Clostridium difficile*

Urogenital infection
- Usual triggers
- *Chlamydia trachomatis*
- Unusual triggers
- ?*Ureaplasma urealyticum*

Respiratory infection
- ?*Chlamydia pneumoniae*

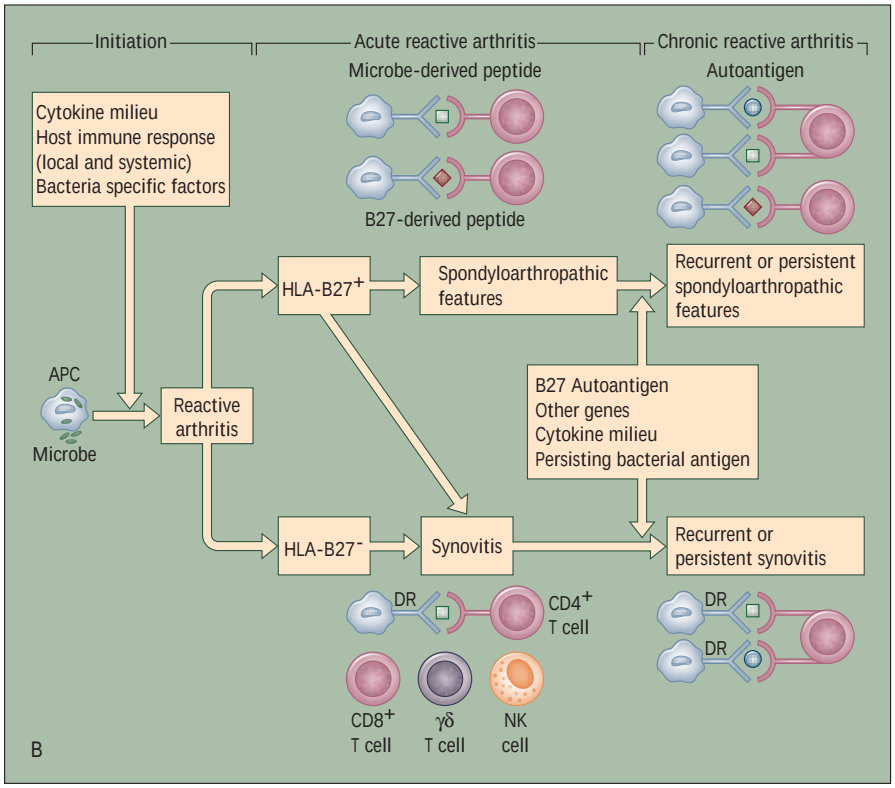

FIGURE 5-32. Mechanisms of reactive arthritis. **A,** Bacterial infections that trigger reactive arthritis. Reactive arthritis is an aseptic inflammatory arthritis developing in an immunologically sensitized host with nonproliferating antigens thought to be present in the joint. The sensitization is usually triggered by chlamydial urethritis, cervicitis, or enteric infection with *Shigella*, *Yersinia*, or *Campylobacter* in a genetically susceptible individual. HLA-B27 is the major currently known genetic risk factor. There has been a dramatic increase of reactive arthritis and related spondyloarthropathies in sub-Saharan Africa resulting from the current epidemic of HIV [31]. This is all the more remarkable given the almost complete absence of HLA-B27 in Bantu populations of Africa, and the fact that the HIV-associated reactive arthritis in Eurocaucasoid populations retains its strong association with HLA-B27. **B,** Schematic representation of the mechanism (pathogenesis) of reactive arthritis. In the figure, *squares* represent microbe-derived peptide, *diamonds* represent B27-derived peptide, and *circles* represent autoantigen. (**B** *courtesy of* Khan and Sieper [55]; with permission.)

Diagnosis of Reactive Arthritis

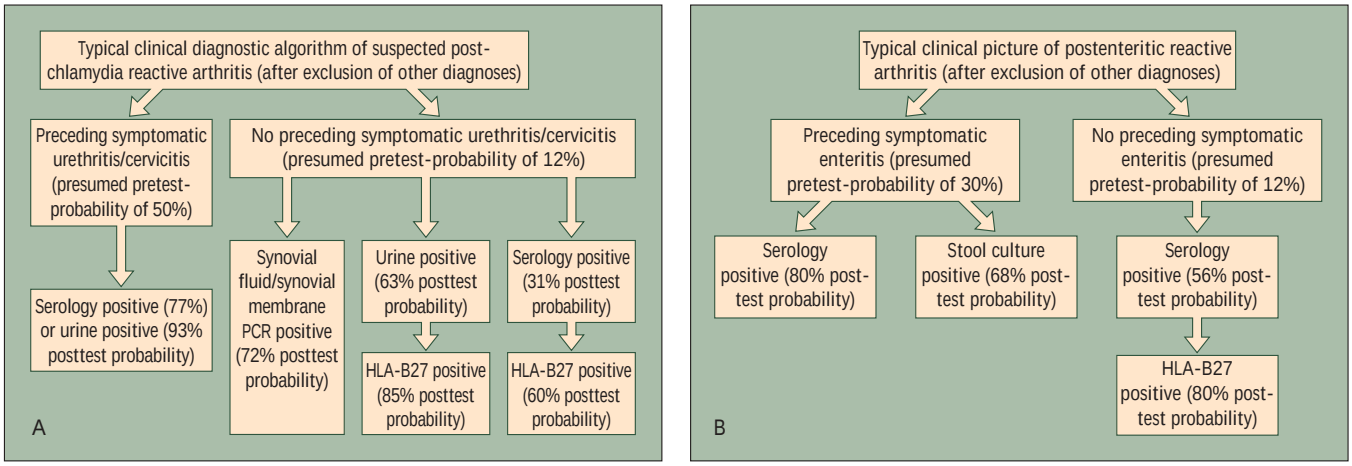

FIGURE 5-33. Diagnosis of reactive arthritis: typical clinical diagnostic algorithm of chlamydia-induced (**A**) and postenteritic (**B**) reactive arthritis (after exclusion of other diagnoses). PCR—polymerase chain reaction. (*Courtesy of* Khan and Sieper [55]; with permission.)

Treatment of Reactive Arthritis

The nonsteroidal anti-inflammatory drugs (NSAIDs) form the basis of therapy, and they should be used regularly in full therapeutic anti-inflammatory dose over an extended period [55,97]. The patient should be advised against using NSAIDs occasionally or for their analgesic effect only. Joint aspiration and intra-articular corticosteroid administration of triamcinolone may help obtain prompt and prolonged relief from severe and persistent synovitis, only after septic arthritis has been excluded. The differential diagnosis from septic arthritis may be sometimes difficult, and short hospitalization may be needed for patients with severe arthritis. Antibiotic treatment should be initiated if true joint infection is not excluded. Joint rest and even temporary splinting may be needed in severe cases to alleviate pain, but should be used sparingly because it may result in muscle wasting. Physical therapy is valuable during convalescence to regain muscle strength and full range of joint motion. A comfortable pair of shoes and shoe inserts to alter weight bearing may help the patient with painful feet.

In a very severe case of acute reactive arthritis in which many joints are affected and NSAIDs alone have failed, a short course of oral corticosteroids may be needed, tapering down the dose according to improvement [55,97,118]. It is advisable to avoid prolonged low-dose oral corticosteroid therapy in chronic cases because it is rarely effective. Sulfasalazine may benefit patients with chronic disease; other "disease-modifying" drugs can be tried in some patients with persistent polyarthritis. Infliximab and etanercept have been found effective in treating severe reactive arthritis, psoriatic arthritis, recalcitrant enthesitis and dactylitis, as well as severe uveitis [119–123]. Skin lesions are treated with topical corticosteroids or keratinolytic agents such as salicylic acid ointment. In severe, cases, retinoids or methotrexate are most commonly used. Acute anterior uveitis must be diagnosed and treated promptly to prevent synchiae and other resultant complications; the inflammation may affect, on rare occasions, even the posterior uveal tract.

There is no benefit of antimicrobial treatment in patients with reactive arthritis and undifferentiated oligoarthritis. Antibiotic treatment of the triggering infection is only recommended if the presence of infection can still be identified after the onset of arthritis. For example, in Yersinia spp infections, the aim of such antibiotic therapy is to minimize the spread of infection within the family. However, a cautious approach should be exercised because antibiotic treatment may prolong the carrier state in some forms of enteritis, and short-term antibiotic treatment does not influence the course of postenteric reactive arthritis. It is obvious that once the trigger has been pulled, the chain of events takes its path anyway. Early treatment of patients with urogenital chlamydial infection in endemic areas has resulted in decreasing subsequent development of reactive arthritis, and vigorous antibiotic treatment of chlamydial reinfections significantly reduced relapses of reactive arthritis. In one study, a 3-month treatment with lymecycline showed some benefit for patients with chlamydial-induced reactive arthritis [55,97].

Recent studies indicate that prolonged antibiotic therapy is unlikely to be beneficial most patients, but a follow-up study of patients who 4 to 7 years previously had been treated with a 3-month course of ciprofloxacin or placebo indicates that the HLA-B27–positive subgroup of patients with reactive arthritis may benefit in the long run from ciprofloxacin therapy [121,122]. However, these promising findings from a small study need to be confirmed in future large studies.Psoriatic Arthritis

Psoriatic Arthritis

A. CLINICAL FEATURES OF PSORIATIC ARTHRITIS IN REPORTED SERIES

Feature	Wright	Little	Roberts	Leonard	Krammer	Scarpa	Gladman
Asymmetric oligoarthritis	53	?	?	63	54*	16.1	11†
Symmetric polyarthritis	31	?	79	23	25*	39	19‡
Distal	3	?	28*	3	?	7.5	12
Back	10	?	5*	7	21	21	2§
Mutilans	?	?	5*	3	?	2.3	16
Sacroiliitis	87	30	?	30	?	16	27

**Includes patients with only distal joints involved; includes more than one category.*
† Includes symmetric oligoarthritis.
‡ Includes asymmetric polyarthritis.
§ Includes peripheral joint and back involvement.

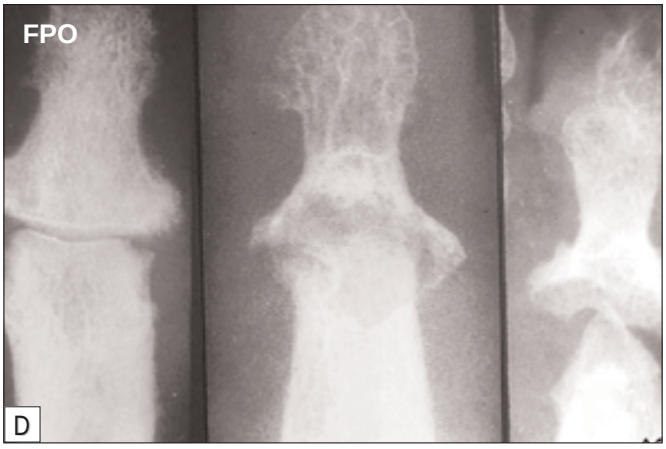

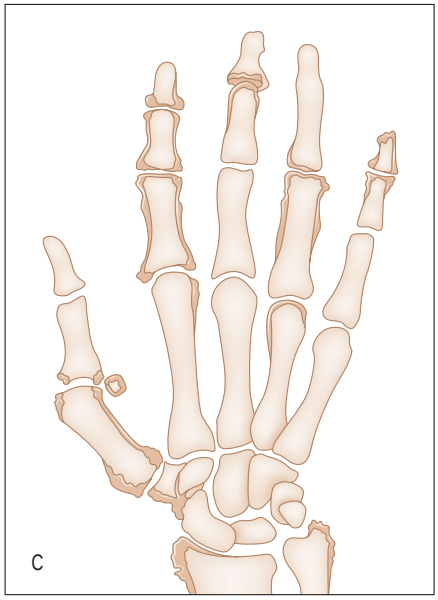

FIGURE 5-34. Psoriatic arthritis is an inflammatory arthritis associated with psoriasis. The exact prevalence of each of its many forms has been difficult to establish (**A**; *numbers in columns are percents*). The disease pattern may change with time in an individual patient, and some patients may show overlapping features. Psoriasis and psoriatic arthritis are relatively more common in whites and are very uncommon among Africans, Chinese, and Native North Americans of unmixed ancestry. Distal interphalangeal joints are frequently affected in psoriatic arthritis (**B–D**). The nails often show pitting (**E**), discoloration, onycholysis (*see* Fig. 5-29*C*), thickening, and ridging. The fingers or toes may show diffused swelling (sausage digits) due to dactylitis resulting from tenosynovitis, arthritis, and periosteitis (**B,F,J**).

(*Continued on next page*)

FIGURE 5-34. (*Continued*) An asymmetric oligoarthritis is noted in 40% and asymmetric polyarthritis in 35%; this latter subgroup has the more erosive, deforming, and disabling disease (**G,H**). Radiographs of the involved joints in a patient with psoriatic arthritis show soft-tissue swelling, periosteitis, juxta-articular hyperostosis, or mild erosions or severe joint destruction in some joints (**D**) and bony fusions in others (**C**). There is often lack of juxta-articular rarefaction (**I**). Sacroiliitis occurs in up to 20% of patients and 5% show predominant spondylitis with radiographic findings that can resemble those seen with reactive arthritis (*see* Fig. 5-31). **G,** Opera glass hand. There is marked resorption of thumb and index finger and to a lesser extent the fourth and fifth fingers, with sparing of middle finger. The resorption of thumb and index finger has resulted in the "telescoping" or "opera glass" deformity, characteristic of severe psoriatic arthritis. Psoriatic lesions on the palm are also evident along with the wrist swelling. Palmar and plantar skin lesions of psoriasis can sometimes resemble those seen in patients with reactive arthritis (*see* Figs. 5-29*A* and *B*). **J,** "Sausage digits" due to dactylitis. Achilles tendonitis and plantar fasciitis (due to enthesitis) can also occur, as is seen in some patients with reactive arthritis (*see* Figs. 5-28*F* and *G*) and other forms of spondyloarthropathies. (**B** *from* Perlman and Barth [124]; **D, G, H, J** *from* the American College of Rheumatology [83]; with permission.)

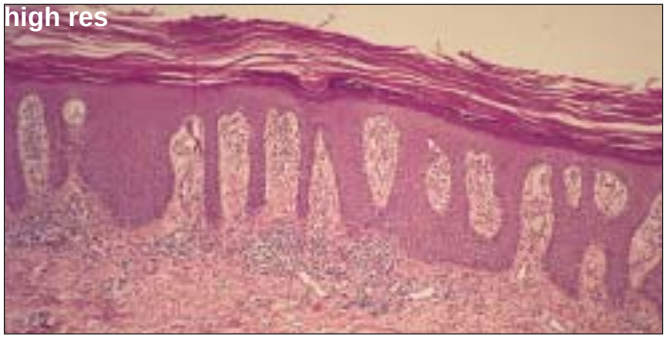

FIGURE 5-35. Histologic specimen of psoriasis. Psoriasis is a disease of abnormal keratinocyte proliferation (scale production) accompanied by an inflammatory component (redness, heat, itch) induced by T cells, but the precise cause is unknown. The activated T cells in the epidermis are predominantly CD8+, whereas those in the dermis are mostly CD4+. The infiltration of CD4+ cells precedes that of CD8+ cells. The epidermal CD8+ T cells possessing receptor are stimulated by a triggering factor (as yet unknown) and produce cytokines (including tumor necrosis factor) that stimulate keratinocytes and cause inflammation. These keratinocytes produce cytokines that in turn stimulate T cells.

Miscellaneous Forms of Disease

A. B27-ASSOCIATED "FORMES FRUSTES"

- Chronic enthesitis (enthesopathies)
- Dactylitis ("sausage" digits)
- Keratoderma (pustular psoriasis)
- Aortic insufficiency with heart block
- Acute anterior uveitis (acute iritis)
- Symptomatic spondylitis without sacroiliitis

B. SYMPTOMS AND SIGNS OF UNDIFFERENTIATED SPONDYLOARTHROPATHIES IN FAMILIES OF PATIENTS WITH ANKYLOSING SPONDYLITIS

Symptoms and Signs	Reference	Year	Relatives, *n*	Relative Frequencies, %
Sacroiliitis without AS	Emery	1967	188	11
	Daneo	1977	37	16
	Christiansen	1977	63	11
	Calin	1983	282	7*
	LeClerco	1984	261	9
	van der Linden	1984	101	7
	Calin	1983	282	38
Inflammatory back pain	Khan	1985	100	9†
	Khan	1985	86	15†
Chest pain	van der Linden	1988	405	11†

* *Minimal frequency, because only 70 (65%) of 107 symptomatic relatives were examined.*
† *Only individuals without radiographic changes.*

FIGURE 5-36. Undifferentiated spondyloarthropathies. **A** and **B,** the concept of spondyloarthropathies has expanded to include undifferentiated forms of the disease (*see* the introduction). In many, if not most patients, the spondyloarthropathies start in an undifferentiated form until they evolve into a clinical picture that fits the diagnosis of ankylosing spondylitis, reactive arthritis, and so on. AS—ankylosing spondylitis. (**B** *adapted from* Zeidler *et al*. [23].)

REPRESENTATIVE STUDIES ON THE LIKELIHOOD OF SPONDYLOARTHROPATHIES WITH ACUTE ANTERIOR UVEITIS

Study	Conclusions
Haarr	34% of patients with acute iritis had AS
Beckingsale *et al*.	60% of patients with HLA-B27–associated iritis had significant back pain
Saari *et al*.	51% of patients with HLA-B27–associated acute anterior uveitis had rheumatic disease
Russell *et al*.	63% of patients with acute anterior uveitis had sacroiliitis by radionuclide scan
Stanworth and Sharp	42% of patients with nongranulomatous anterior uveitis had AS or RS
Pedersen	33% of patients with acute anterior uveitis had rheumatic disease
Vinje *et al*.	35% of patients with acute anterior uveitis had radiographic sacroiliitis
Linssen *et al*.	73% of HLA-B27–positive patients with acute anterior uveitis had rheumatic disease
Feltkamp	90% of patients with HLA-B27–associated acute anterior uveitis had definite or possible AS
Rosenbaum	84% of patients with HLA-B27–associated acute anterior uveitis had AS, RS, or incomplete RS

FIGURE 5-37. Rheumatic disease with iritis. Acute anterior uveitis has a strong association with spondyloarthropathies and with HLA-B27 even in the absence of any associated spondyloarthropathy. It is also associated with Crohn's disease and ulcerative colitis, with or without associated (enteropathic) arthritis. AS—ankylosing spondylitis; RS—Reiter's syndrome. (*Adapted from* Rosenbaum [125].)

References

1. van der Linden S, Pascual E, eds.: Spondyloarthropathies. *Best Pract Res Clin Rheumatol* 2002, 16:495–705.
2. Calin A, Taurog J, (eds.): *The Spondylarthritides*. New York: Oxford University Press; 1998.
3. Khan MA: Update on spondyloarthropathies. *Ann Intern Med* 2002, 136:896–907.
4. Rudwaleit M, van der Heijde D, Khan MA, *et al*.: How to diagnose axial spondyloarthritis early. *Ann Rheum Dis* 2004, 63:535–543.
5. Cassidy JT, Petty RE, eds.: *Textbook of Pediatric Rheumatology*, edn 4. Philadelphia: WB Saunders; 2001.
6. Brewerton DA, Hart FD, Nicholls A, *et al*.: Ankylosing spondylitis and HL-A27. *Lancet* 1973, 1:904–907.
7. Khan MA: HLA-B27 and its subtypes in world populations. *Curr Opin Rheumatol* 1995, 7:263–269.
8. Brown MA, Pile KD, Kennedy LG, *et al*.: HLA class I associations of ankylosing spondylitis in the white population in the United Kingdom. *Ann Rheum Dis* 1996, 55:268–270.
9. Martinez-Borra J, Lopez-Vazquez A, Gelaz MA, *et al*.: HLA-B27 alone rather than B27-related class I haplotypes contributes to ankylosing spondylitis susceptibility. *Hum Immunol* 2000, 61:131–139.
10. Sims AM, Wordsworth BP, Brown MA: Genetic susceptibility to ankylosing spondylitis. *Curr Mol Med* 2004, 4:13–20.
11. Laval SH, Timms A, Edwards S, *et al*.: Whole-genome screening in ankylosing spondylitis: evidence of non-MHC genetic-susceptibility loci. *Am J Hum Genet* 2001, 68:916–926.
12. Zhang G, Luo J, Bruckel J, *et al*.: Genetic studies in familial ankylosing spondylitis susceptibility. *Arthritis Rheum* 2004, 50:2246–2254.

13. Sieper J: Disease mechanisms in reactive arthritis. *Curr Rheumatol Rep* 2004, 6:110–116.
14. Brown MA, Brophy S, Bradbury L, *et al.*: Identification of major loci controlling clinical manifestations of ankylosing spondylitis. *Arthritis Rheum* 2003, 48:2234–2239.
15. Khan MA, Ball EJ: Ankylosing spondylitis and genetic aspects. *Best Pract Res Clin Rheumatol* 2002, 16:675–690.
16. Nair RP, Stuart P, Henseler T, *et al.*: Localization of psoriasis-susceptibility locus PSORS1 to a 60-kb interval telomeric to HLA-C. *Am J Hum Genet* 2000, 66:1833–1844.
17. Khan MA, van der Linden SM: A wider spectrum of spondyloarthropathies. *Semin Arthritis Rheum* 1990, 20:107–113.
18. Olivieri I, Salvarani C, Cantini F, *et al.*: Ankylosing spondylitis and undifferentiated spondyloarthropathies: a clinical review and description of a disease subset with older age of onset. *Curr Opin Rheumatol* 2001, 13:280–284.
19. Braun J, Khan MA, Sieper J: Enthesitis and ankylosis in spondyloarthropathy: what is the target of the immune response? *Ann Rheum Dis* 2000, 59:985–994.
20. François RJ, Braun J, Khan MA: Entheses and enthesitis: a histopathological review and relevance to spondyloarthropathies. *Curr Opin Rheumatol* 2001, 13:255–264.
21. McGonagle D, Marzo-Ortega H, Benjamin M, Emery P: Report on Second International Enthesitis Workshop. *Arthritis Rheum* 2003, 48:896–905.
22. Boyer GS, Templin DW, Bowler A, *et al.*: Spondyloarthropathy in the community: clinical syndromes and disease manifestations in Alaskan Eskimo populations. *J Rheumatol* 1999, 26:1537–1544.
23. Zeidler H, Mau W, Khan MA: Undifferentiated spondyloarthropathies. *Rheum Dis Clin North Am* 1992, 18:187–202.
24. Fernandez-Melon J, Munoz-Fernandez S, Hidalgo V, *et al.*: Uveitis as the initial clinical manifestation in patients with spondyloarthropathies. *J Rheumatol* 2004, 31:524–527.
25. Monnet D, Breban M, Hudry C, *et al.*: Ophthalmic findings and frequency of extraocular manifestations in patients with HLA-B27 uveitis: a study of 175 cases. *Ophthalmology* 2004, 111:802–809.
26. Bergfeldt L: HLA-B27–associated cardiac disease. *Ann Intern Med* 1997, 127:621–629.
27. Gran JT, Husby G, Hordvik M: Prevalence of ankylosing spondylitis in males and females in a young middle-aged population of Tromso, northern Norway. *Ann Rheum Dis* 1985, 44:359–367.
28. Braun J, Bollow M, Remlinger G, *et al.*: Prevalence of spondyloarthropathies in HLA-B27 positive and negative blood donors. *Arthritis Rheum* 1998, 41:58–67.
29. Saraux A, Guedes C, Allain J, *et al.*: Prevalence of rheumatoid arthritis and spondyloarthropathy in Brittany, France. *J Rheumatol* 1999, 26:2622–2627.
30. Hukudo S, Minami M, Saito T, *et al.*: Spondyloarthropathies in Japan: nationwide questionnaire survey performed by the Japan Ankylosing Spondylitis Society. *J Rheumatology* 2001, 28:554–559.
31. Mijiyawa M, Oniankitan O, Khan MA: Spondyloarthropathies in sub-Saharan Africa. *Curr Opin Rheumatol* 2000, 12:263–268.
32. Dougados M, van der Linden S, Juhlin R, *et al.*: The European Spondyloarthropathy Study Group preliminary criteria for the classification of spondyloarthropathies. *Arthritis Rheum* 1991, 34:1218–1227.
33. Collantes E, Veroz R, Escudero A, *et al.*: Can some cases of 'possible' spondyloarthropathy be classified as 'definite' or 'undifferentiated' spondyloarthropathy? Value of criteria for spondyloarthropathies. Spanish Spondyloarthropathy Study Group. *Joint Bone Spine* 2000, 67:516–520.
34. Erturk M, Alaca R, Tosun E, Duruoz MT: Evaluation of the Amor and ESSG classification criteria for spondyloarthropathies in a Turkish population. *Rev Rhum Engl Ed* 1997, 64:293–300.
35. Boyer GS, Templin DW, Bowler A, *et al.*: A comparison of patients with spondyloarthropathy seen in specialty clinics with those identified in a community-wide epidemiologic study. Has the classic case misled us? *Arch Intern Med* 1997, 157:2111–2117.
36. Olivieri I, van Tubergen A, Salvarani C, van der Linden S: Seronegative spondyloarthritides. *Best Pract Res Clin Rheumatol* 2002, 16:723–739.
37. Khan MA: HLA-B27 polymorphism and association with disease (editorial). *J Rheumatol* 2000, 27:1110–1114.
38. Feltkamp TE, Mardjuadi A, Huang F, Chou C-T: Spondyloarthropathies in eastern Asia. *Curr Opin Rheumatol* 2001, 13:285–290.
39. D'Amato M, Fiorillo MT, Galeazzi M, *et al.*: Frequency of the new HLA-B*2709 allele in ankylosing spondylitis patients and healthy individuals. *Dis Markers* 1995, 12:215–217.
40. Khan MA: Ankylosing spondylitis: clinical features. In *Rheumatology*, edn 3. Edited by Hochberg M, *et al.* London: Mosby; 2003:1161–1181.
41. Francois RJ, Gardner DL, Degrave EJ, Bywaters EG: Histopathologic evidence that sacroiliitis in ankylosing spondylitis is not merely enthesitis. *Arthritis Rheum* 2000, 43:2011–2024.
42. Braun J, Sieper J: The sacroiliac joint in the spondyloarthropathies. *Curr Opin Rheumatol* 1996, 7:275–283.
43. Laloux L, Voisin M-C, Allain J, *et al.*: Immunohistological study of entheses in spondyloarthropathies: comparison in rheumatoid arthritis and osteoarthritis. *Ann Rheum Dis* 2001, 60:316–321.
44. Maksymowych W: Ankylosing spondylitis: at the interface of bone and cartilage. *J Rheumatol* 1999, 27:2295–2301.
45. Khan MA, ed.: Ankylosing spondylitis and related spondyloarthropathies. In *Spine: State of the Art Reviews*. Philadelphia: Hanley & Belfus; 1990.
46. Miron SD, Khan MA, Wiesen E, *et al.*: The value of quantitative sacroiliac scintigraphy in detection of sacroiliitis. *Clin Rheumatol* 1983, 2:407–414.
47. Khan MA, Kushner I: Diagnosis of ankylosing spondylitis. In *Progress in Clinical Rheumatology*, vol I. Edited by Cohen AS. New York: Grune and Stratton; 1984:145–178.
48. Mader R: Atypical clinical presentation of ankylosing spondylitis. *Semin Arthritis Rheum* 1999, 29:191–196.
49. van der Heijde D: New directions in classification and outcome assessment in ankylosing spondylitis. *Curr Rheumatol Rep* 2004, 6:98–101.
50. van der Linden S, Valkenburg HA, Cats A: Evaluation of diagnostic criteria for ankylosing spondylitis: a proposal for modification of the New York criteria. *Arthritis Rheum* 1984, 27:361–368.
51. Inman RD, Whittum-Hudson JA, Schumacher HR, Hudson AP: Chlamydia and associated arthritis. *Curr Opin Rheumatol* 2000, 12:254–262.
52. Granfors K, Märker-Hermann E, De Keyser P, *et al.*: The cutting edge of spondyloarthropathy research in the millennium. *Arthritis Rheum* 2002, 46:606.
53. Flores D, Marquez J, Garza M, Espinoza LR: Reactive arthritis: newer developments. *Rheum Dis Clin North Am* 2003, 29:37–59.
54. Gaston H, Lillicrap MS: Arthritis associated with enteric infection. *Best Pract Res Clin Rheumatol* 2003, 17:219–229.
55. Khan MA, Sieper J: Reactive arthritis. In *Arthritis and Allied Conditions: A Textbook of Rheumatology*, edn 15. Edited by Koopman WJ. Baltimore: Lippincott Williams & Wilkins; 2004 (in press).
56. Sieper J, Braun J, Kingsley GH: Report on the Fourth International Workshop on Reactive Arthritis. *Arthritis Rheum* 2000, 43:720–734.
57. Schwartzenberg JM, Smith DD, Lindsley HB: Bacillus Calmette-Guerin-associated arthropathy mimicking undifferentiated spondyloarthropathy. *J Rheumatol* 1999, 26:933–935.
58. Hannu T, Puolakkainen M, Lerisalo-Repo M: Chlamydia pneumonia as a trigger agent in reactive arthritis. *Rheumatology* 1999, 42:1386–1396.
59. Amor B: Reiter's syndrome: diagnosis and clinical features. *Rheum Dis Clin North Am* 1998, 24:677–695.
60. Toivanen A, Toivanen P: *Reactive Arthritis*. Boca Raton, FL: CRC Press; 1988:1–13.
61. Mody GM, Parke FA, Reveille JD: Articular manifestations of human immunodeficiency virus infection. *Best Pract Res Clin Rheumatol* 2003, 17:265–287.
62. Winchester R: Psoriatic arthritis and the spectrum of the syndromes related to the SAPHO (synovitis, acne, pustulosis, hyperostosis, and osteitis) syndrome. *Curr Opin Rheumatol* 1999, 11:251–256.
63. Njobvu P, McGill P: Psoriatic arthritis and human immunodeficiency virus infection in Zambia. *J Rheumatol* 2000, 27:1699–1702.
64. Hohler T, Marker-Hermann E: Psoriatic arthritis: clinical aspects, genetics, and the role of T cells. *Curr Opin Rheumatol* 2001, 13:273–279.
65. Gladman DD, Brockbank J: Psoriatic arthritis. *Expert Opin Investig Drugs* 2000, 9:1511–1522.
66. Moll JMH, Wright V: Psoriatic arthritis. *Semin Arthritis Rheum* 1973, 3:55–78.
67. Bennett DL, Ohashi K, El-Khoury GY: Spondyloarthropathies: ankylosing spondylitis and psoriatic arthritis. *Radiol Clin North Am* 2004, 42:121–134.
68. de Vlam K, Mielants H, Cuvelier C, *et al.*: Spondyloarthropathy is underestimated in inflammatory bowel disease: prevalence and HLA association. *J Rheumatol* 2000, 27:2860–2865.
69. Quiero R, Maiz O, Intxausti J, *et al.*: Subclinical sacroiliitis in inflammatory bowel disease: a clinical and follow-up study. *Clin Rheumatol* 2000, 19:445–449.
70. De Keyser F, Baeten D, Van den Bosch F, *et al.*: Gut inflammation and spondyloarthropathies. *Curr Rheumatol Rep* 2002, 4:525–532.
71. Burgos-Vargas R: The juvenile-onset spondyloarthritides. *Rheum Dis Clin North Am* 2002, 28:531–560.
72. Khan MA: A worldwide overview: the epidemiology of HLA-B27 and associated spondyloarthritides. In *Spondylarthritides*. Edited by Calin A, Taurog J. New York: Oxford University Press; 1998:17–26.
73. van der Linden: Ankylosing spondylitis. In *Textbook of Rheumatology*, edn 5. Edited by Kelly WN, Harris ED, Ruddy S, Sledge CB. Philadelphia: WB Saunders; 1996:969–982.

74. Gratacos J, Collado A, Pons F, *et al.*: Significant loss of bone mass in patients with early, active ankylosing spondylitis: a follow up study. *Arthritis Rheum* 1999, 42:2319–2324.
75. Feldtkeller E, Khan MA, van der Linden S, *et al.*: Age at disease onset and diagnosis delay in HLA-B27 negative vs. positive patients with ankylosing spondylitis. *Rheumatol Int* 2003, 23:61–66.
76. Khan MA, Kushner I, Braun WE: Comparison of clinical features of HLA-B27 positive and negative patients with ankylosing spondylitis. *Arthritis Rheum* 1977, 20:909–912.
77. Mitra D, Elvins DM, Speden DJ, Collins AJ: The prevalence of vertebral fractures in mild ankylosing spondylitis and their relationship to bone mineral density. *Rheumatology* 2000, 39:85–89.
78. Tico N, Ramon S, Garcia-Ortun F, *et al.*: Traumatic spinal cord injury complicating ankylosing spondylitis. *Spinal Cord* 1998, 36:349–352.
79. Finkelstein JA, Chapman JR, Mirza S: Occult vertebral fractures in ankylosing spondylitis. *Spinal Cord* 1999, 37:444–447.
80. Resnick D, Williamson S, Alazraki N: Focal spinal abnormalities on bone scans in ankylosing spondylitis: a clue to the presence of fracture or pseudoarthrosis. *Clin Nucl Med* 1995, 6:213–217.
81. Shih TT, Chen PQ, Li YW, Hsu CY: Spinal fractures and pseudoarthrosis complicating ankylosing spondylitis: MRI manifestation and clinical significance. *J Comput Assist Tomogr* 2001, 25:164–170.
82. Little H, Swinson DR, Cruickshank B: Upward subluxation of the axis in ankylosing spondylitis: a clinical pathologic report. *Am J Med* 1976, 60:279–285.
83. American College of Rheumatology: Core Curriculum, Collection One [compact disk]. 1993–2003.
84. Levine DS, Forbat SM, Saifuddin A: MRI of the axial skeletal manifestations of ankylosing spondylitis. *Clin Radiol* 2005, 59:400–413.
85. Berens DL: Roentgen features of ankylosing spondylitis. *Clin Orthop* 1971, 74:20–33.
86. Sieper J, van der Heijde D: Analyzing chronic spinal changes in ankylosing spondylitis: a systematic comparison of conventional x-rays with magnetic resonance imaging (MRI) using established and new scoring systems. *Ann Rheum Dis* 2005, in press.
87. Khan MA, Khan MK, Kushner I: Survival among patients with ankylosing spondylitis: a life-table analysis. *J Rheumatol* 1981, 8:86–90.
88. Callahan LF, Pincus T: Mortality in the rheumatic diseases. *Arthritis Care Res* 1995, 8:229–241.
89. Feltkamp TE: Factors involved in the pathogenesis of HLA-B27 associated arthritis. *Scand J Rheumatol Suppl* 1995, 101:213–217.
90. Khan MA: Spondyloarthropathies: editorial overview. *Curr Opin Rheumatol* 1994, 6:351–353.
91. Amor B, Dougados M, Khan MA, *et al.*: Management of refractory ankylosing spondylitis and related spondyloarthropathies. *Rheum Dis Clin North Am* 1995, 21:117–128.
92. Arnett FC, Jr, Khan MA, Willkins RF: A new look at ankylosing spondylitis. *Patient Care* 1989, 30:82–101.
93. Roddis M, Carter RW, Sun MY, *et al.*: Fully functional HLA B27-restricted CD4+ as well as CD8+ T cell responses in TCR transgenic mice. *J Immunol* 2004, 172:155–161.
94. Rudwaleit M, Listing J, Brandt J, *et al.*: Prediction of a major clinical response (BASDAI 50) to TNF-α blockers in ankylosing spondylitis. *Ann Rheum Dis* 2004, in press.
95. Marzo-Ortega H, McGonagle D, O'Connor P, Emery P: Efficacy of etanercept for treatment of Crohn's-related spondyloarthritis but not colitis. *Ann Rheum Dis* 2003, 62:74–76.
96. Clegg DO, Reda DJ, Abdellatif M: Comparison of sulfasalazine and placebo for the treatment of axial and peripheral articular manifestations of the seronegative spondyloarthropathies. *Semin Arthritis Rheum* 1999, 42:2325–2329.
97. Braun J, Sieper J, Khan MA: Recent advances in pharmacotherapy of spondyloarthropathies. In *Modern Therapeutics in Rheumatic Diseases*. Totowa, NJ: Humana Press; 2002:595–603.
98. Roychaudhry B, Bintley-Bagot S, Hunt J, Tunn EJ: Methotrexate in severe ankylosing spondylitis: a randomized placebo-controlled, double-blind observer study [abstract]. *Rheumatology* 2001, 40(supple 1):43.
99. Baeten D, Kruithof E, Van den Bosch F, *et al.*: Systemic safety follow-up in a cohort of 107 patients with spondyloarthropathy treated with infliximab: a new perspective on the role of host defense in the pathogenesis of the disease? *Ann Rheum Dis* 2003, 62:829–834.
100. Meador R, Hsia E, Kitumnauypong T, Schumacher HR: TNF involvement and anti-TNF therapy of reactive and unclassified arthritis. *Clin Exp Rheumatol* 2002, 20(6 suppl 28):S130–S144.
101. Braun J, Brandt J, Listing J, *et al.*: Biologic therapies in the spondyloarthritis: new opportunities, new challenges. *Curr Opin Rheumatol* 2003, 15:394–407.
102. Braun J, Brandt J, Listing, J, *et al.*: Long-term efficacy and safety of infliximab in the treatment of ankylosing spondylitis: an open, observational, extension study of a three-month, randomized, placebo-controlled trial. *Arthritis Rheum* 2003, 48:2224–2233.
103. Brandt J, Khariouzov A, Listing J, *et al.*: Six-month results of a double-blind, placebo-controlled trial of etanercept treatment in patients with active ankylosing spondylitis. *Arthritis Rheum* 2003, 48:1667–1675.
104. Landewe R, Rump B, Van Der Heijde D, *et al.*: Which patients with ankylosing spondylitis should be treated with tumor necrosis factor inhibiting therapy? A survey among Dutch rheumatologists. *Ann Rheum Dis* 2004, 63:530–534.
105. Braun J, Pham T, Sieper J, *et al.*: International ASAS consensus statement for the use of anti-tumour necrosis factor agents in patients with ankylosing spondylitis. *Ann Rheum Dis* 2003, 62:817–824.
106. Pham T, van der Heijde D, Calin A, *et al.*: Initiation of biological agents in patients with ankylosing spondylitis: results of a Delphi study by the ASAS Group. *Ann Rheum Dis* 2003, 62:812–816.
107. Maksymowych WP, Jhangri GS, Leclercq S, *et al.*: An open study of pamidronate in the treatment of refractory ankylosing spondylitis. *J Rheumatol* 1998, 25:714–717.
108. Maksymowych WP, Lambert R, Jhangri GS, *et al.*: Clinical and radiological amelioration of refractory peripheral spondyloarthritis by pulse intravenous pamidronate therapy. *J Rheumatol* 2001, 28:144–155.
109. Breban M, Gombert B, Amor B, Dougados M: Efficacy of thalidomide in the treatment of refractory ankylosing spondylitis. *Arthritis Rheum* 1999, 42:580–581.
110. Wendling D, Toussirot E, Michel F: Thalidomide: a comeback? *Joint Bone Spine* 2001, 67:259–261.
111. Lorig KR, Mazonson PD, Holman HR: Evidence suggesting that health education for self-management in patients with chronic arthritis has sustained health benefits while reducing health care costs. *Arthritis Rheum* 1993, 36:439–446.
112. Pal B: What counseling do patients with ankylosing spondylitis receive? Results of a questionnaire survey. *Clin Rheumatol* 1998, 17:306–308.
113. Schmeid P, Baumberger H: *Morbus Bechterew*, edn 3. Munchen: Urban and Fischer Verlag; 2003.
114. Khan MA: *Ankylosing Spondylitis: The Facts*. Oxford, UK: Oxford University Press; 2002.
115. Koopman WJ: *Arthritis and Allied Conditions: A Textbook of Rheumatology*, edn 14. Philadelphia: Lippincott Williams & Wilkins; 2001.
116. Khan MA, Skosey JL: Ankylosing spondylitis and related spondyloarthropathies. In *Immunological Diseases*, edn 4. Edited by Samter M, Talmage DW, Frank MM, *et al.* Boston: Little, Brown; 1988:1509–1538.
117. Mustafa K, Khan MA: Recognizing and managing reactive arthritis. *J Musculoskeletal Med* 1996, 13:28–41.
118. Dougados M, Revel M, Khan MA: Management of spondyloarthropathy. In *Therapy of Systemic Rheumatic Disorders*. Edited by van de Putte LBA, Williams HJ, van Riel P, Furst DE. New York: Marcel Dekker; 1998:375–406.
119. Oili KS, Niinisalo H, Korpilahde T, Virolainen J: Treatment of reactive arthritis with infliximab. *Scand J Rheumatol* 2003, 32:122–124.
120. Meader R: TNF involvement and anti-TNF therapy of reactive and unclassified arthritis. *Clin Exp Rheumatol* 2002, 20(suppl 28):s130–s134.
121. Mease PJ: Disease-modifying antirheumatic drug therapy for spondyloarthropathies: advances in treatment. Curr Opin Rheumatol 2003, 15:205–212.
122. Yli-Kerttula T, Luukainen R, Moettoenen T, *et al.*: Effect of a three-month course of ciprofloxacin on the late prognosis of reactive arthritis. *Ann Rheum Dis* 2003, 62:880–884.
123. Rosenbaum JT, Smith JP: Anti-TNF therapy for eye involvement in spondyloarthropathy. *Clin Exp Rheumatol* 2002, 20(suppl 28):S143–S145.
124. Perlman SG, Barth WF: Psoriatic arthritis: diagnosis and management. *Compr Ther* 1979, 5:60–66.
125. Rosenbaum JT: Acute anterior uveitis and spondyloarthropathies. *Rheum Dis Clin North Am* 1992, 18:143–151.